

Tissue coverage of a hydrophilic polymer-coated zotarolimus-eluting stent vs. a fluoropolymer-coated everolimus-eluting stent at 13-month follow-up: an optical coherence tomography substudy from the RESOLUTE All Comers trial

Juan Luis Gutiérrez-Chico¹, Robert Jan van Geuns¹, Evelyn Regar¹, Willem J. van der Giessen¹, Henning Kelbæk², Kari Saunamäki², Javier Escaned³, Nieves Gonzalo³, Carlo di Mario⁴, Francesco Borgia⁴, Eveline Nüesch⁵, Héctor M. García-García⁶, Sigmund Silber⁷, Stephan Windecker⁸, and Patrick W. Serruys^{1*}

¹Erasmus Medical Centre, Thoraxcenter, Ba583a, 's-Gravendijkwal 230, 3015 CE Rotterdam, The Netherlands; ²Rigshospitalet, Copenhagen, Denmark; ³Hospital Clínico San Carlos, Madrid, Spain; ⁴Royal Brompton Hospital, London, UK; ⁵Institute of Social and Preventive Medicine, University of Bern, Bern, Switzerland; ⁶Cardialysis BV, Rotterdam, The Netherlands; ⁷Kardiologische Gemeinschaftspraxis und Praxisklinik, Munich, Germany; and ⁸Schweizerisches Herzzentrum—Inselspital, Bern, Switzerland

Received 12 January 2011; revised 19 March 2011; accepted 13 May 2011; online publish-ahead-of-print 9 June 2011

Aims

To compare the tissue coverage of a hydrophilic polymer-coated zotarolimus-eluting stent (ZES) vs. a fluoropolymer-coated everolimus-eluting stent (EES) at 13 months, using optical coherence tomography (OCT) in an 'all-comers' population of patients, in order to clarify the mechanism of eventual differences in the biocompatibility and thrombogenicity of the devices.

Methods and results

Patients randomized to angiographic follow-up in the RESOLUTE All Comers trial (NCT00617084) at pre-specified OCT sites underwent OCT follow-up at 13 months. Tissue coverage and apposition were assessed strut by strut, and the results in both treatment groups were compared using multilevel logistic or linear regression, as appropriate, with clustering at three different levels: patient, lesion, and stent. Fifty-eight patients (30 ZES and 28 EES), 72 lesions, 107 stents, and 23 197 struts were analysed. Eight hundred and eighty-seven and 654 uncovered struts (7.4 and 5.8%, $P = 0.378$), and 216 and 161 malapposed struts (1.8 and 1.4%, $P = 0.569$) were found in the ZES and EES groups, respectively. The mean thickness of coverage was $116 \pm 99 \mu\text{m}$ in ZES and $142 \pm 113 \mu\text{m}$ in EES ($P = 0.466$). No differences in per cent neointimal volume obstruction (12.5 ± 7.9 vs. $15.0 \pm 10.7\%$) or other areas–volumetric parameters were found between ZES and EES, respectively.

Conclusion

No significant differences in tissue coverage, malapposition, or lumen/stent areas and volumes were detected by OCT between the hydrophilic polymer-coated ZES and the fluoropolymer-coated EES at 13-month follow-up.

Keywords

Tomography, optical coherence • Polymers • Poly(vinylidene fluoride-co-hexafluoropropylene) • Zotarolimus • Everolimus • Drug-eluting stents • Coronary vessels • Angioplasty, transluminal, percutaneous coronary

* Corresponding author. Tel: +31 10 7035260, Fax: +31 10 4369154, Email: jlgutierrez@medynet.com or p.w.j.c.serruys@erasmusmc.nl

Published on behalf of the European Society of Cardiology. All rights reserved. © The Author 2011. For permissions please email: journals.permissions@oup.com.

The online version of this article has been published under an open access model. Users are entitled to use, reproduce, disseminate, or display the open access version of this article for non-commercial purposes provided that the original authorship is properly and fully attributed; the Journal, Learned Society and Oxford University Press are attributed as the original place of publication with correct citation details given; if an article is subsequently reproduced or disseminated not in its entirety but only in part or as a derivative work this must be clearly indicated. For commercial re-use, please contact journals.permissions@oup.com

Introduction

The neointimal healing response after stenting strongly determines the long-term outcome. In the era of bare-metal stents (BMS), the concern was focused on an exaggerated neointimal proliferation, often leading to restenosis, that accounted for 20.0–50.3% of the cases.¹ Drug-eluting stents (DES) have reduced the restenosis rates to 7.9–8.9%,¹ due to their ability to inhibit cellular proliferation. However, since some reports suggested an eventually higher incidence of late and very late stent thrombosis in DES,^{2–5} the concern shifted to the opposite pole: avoiding an incomplete neointimal coverage of the metallic scaffold that might eventually pose a risk for stent thrombosis.^{6–10} Intense research is currently aimed to promote optimal neointimal healing.¹¹

The neointimal healing response can be quantified *in vivo* by invasive imaging techniques. Intravascular ultrasound (IVUS) can quantify neointimal hyperplasia (NIH) and discern whether it is exaggerated, but it cannot assess the completeness of healing, because the thin neointimal layer covering the DES struts is often below IVUS axial resolution (100 μm). Optical coherence tomography (OCT) provides an axial resolution of 10–15 μm , thus enabling accurate evaluation of tissue coverage after stenting. Optical coherence tomography coverage correlates well with histological neointimal healing and endothelialization after stenting in animal models,^{12–15} thus constituting an *in vivo* surrogate to estimate the completeness of neointimal healing.^{14,15} Optical coherence tomography has become an exploratory tool for the evaluation of healing in studies comparing different types of DES.^{16–18}

The polymers releasing the drug play a role in the modulation of the neointimal response after stenting. In the first-generation DES, some polymers were believed to induce allergic reactions and inflammation, resulting in incomplete neointimal healing and ultimately stent thrombosis.^{10,19} The second generation of polymer coatings is designed to enhance biocompatibility and minimize the inflammatory reaction through different approaches.^{16,20} The BioLinx polymer (Medtronic Inc., Santa Rosa, CA, USA) comprises three different polymers: (i) the hydrophobic C10 acts as a drug reservoir for a slow and sustained release, (ii) the hydrophilic polyvinyl-pyrrolidone improves biocompatibility, and (iii) C19 contains both hydrophobic and hydrophilic polyvinyl-pyrrolidone groups playing a role in the control of drug release and in the biocompatibility, respectively. The blend acts as an amphiphilic molecule, with topographic orientation of its hydrophilic components towards the surface in contact with the cells,^{21,22} thus improving the biocompatibility, since hydrophilic polymers do not induce activated monocyte adhesion,²³ which is associated with local inflammation and vascular cell proliferation.²⁴ The BioLinx polymer also enables a finer and more sustained drug elution. In the porcine model, 85% of the drug content is eluted into tissue during the first 60 days and the remainder is completely eluted by 180 days.²⁵ Another contemporary biocompatible polymer is the fluoropolymer, poly(vinylidene fluoride-co-hexafluoropropylene). The fluoropolymer surface is hydrophobic, but elicits a biological response known as 'fluoropassivation' which consists of minimizing the fibrin deposition and thrombogenicity, reducing the inflammatory reaction and enhancing a faster neointimal healing.^{26,27} Preferential affinity of

fluorinated surfaces for albumin, with respect to fibrin, and the inhibitory effect of fluorination on platelets adhesion/activation or leucocytes recruitment have been postulated as mechanisms to explain this phenomenon.

The BioLinx polymer is a component of the Resolute stent (Medtronic), together with the Driver BMS (Medtronic) and the antiproliferative agent zotarolimus, at a dose of 160 $\mu\text{g}/\text{cm}^2$.²¹ The stent has proven excellent clinical and angiographic results in selected groups.^{28–30} The RESOLUTE All Comers trial (NCT00617084) compared for the first time the Resolute zotarolimus-eluting stent (ZES) vs. another DES (XIENCE V, Abbott Vascular, Santa Clara, CA, USA) in an 'all-comers' patient population, with a non-inferiority design.³¹ XIENCE V is an everolimus-eluting stent (EES) at a dose of 100 $\mu\text{g}/\text{cm}^2$ of stent surface, coated with a fluoropolymer, designed to release 80% of the everolimus in the first 30 days after deployment.³² ZES proved to be non-inferior to EES for target-lesion failure, a composite of cardiac death, myocardial infarction, and clinically indicated target-lesion revascularization.³¹ Nevertheless, the interpretation of the stent thrombosis rates is still a matter of dispute: definite stent thrombosis was significantly higher in ZES than in EES (1.2 vs. 0.3%) at 1 year, but there were no significant differences in definite/probable stent thrombosis.³¹ In order to better understand these clinical results, this OCT substudy of the RESOLUTE All Comers trial compares the neointimal coverage of both devices 13 months after implantation.

Methods

The design and main results from the RESOLUTE All Comers have been published elsewhere.³¹ It was an international, multicentre, prospective, randomized, open-label non-inferiority trial comparing the Resolute ZES, with BioLinx polymer vs. the XIENCE V EES, with fluoropolymer coating. Patient eligibility followed a real-world all-comers design, including patients with symptomatic coronary heart disease with every possible presentation or with silent ischaemia, with one or more coronary artery stenoses >50% in 2.25–4.00 mm diameter vessels, susceptible to be treated with either of the two devices. There were no limitations regarding the number of lesions or vessels treated, or lesion length. Exclusion criteria comprised known allergy to anti-platelet/anti-thrombotic regimes, or to any of the components of the two stents of the study. Planned surgery in the following 6 months after PCI was also an exclusion criterion. The primary endpoint was target-lesion failure, a composite of cardiac death, myocardial infarction (not clearly attributable to a non-target vessel), and clinically indicated target-lesion revascularization at 1-year follow-up.

Twenty per cent of the patients were randomly selected for an angiographic substudy, thus undergoing quantitative coronary angiography (QCA) at baseline and repeat angiography at 13-month follow-up. Optical coherence tomography was performed in patients in the angiographic substudy from selected sites in which OCT was available. The sample size was calculated for the angiographic substudy,³¹ but no formal sample size calculation based on an endpoint hypothesis was performed for the OCT substudy, because no evidence about the expected magnitude of the effect was available when the trial was designed. Based on unpublished data and on the expertise of the investigators with other ongoing OCT trials, a minimum number of 50 patients was considered necessary to provide reliable and non-trivial results.

Table 1 Characteristics of the different optical coherence tomography systems^a in the study

	M2	M3	C7
Technique	Occlusive	Non-occlusive	Non-occlusive
Domain	Time	Time	Fourier
Catheter	ImageWire	ImageWire	Dragonfly
Rotation speed (frames/s)	15.6	20	100
Pullback speed (mm/s)	2	3	20
Patients with ZES	1	9	20
Patients with EES	2	9	17
Total	3	18	37

ZES, zotarolimus-eluting stent; EES, everolimus-eluting stent.
^aAll systems and catheters from Lightlab Imaging.

Several clinical, angiographic, and OCT variables were identified as secondary endpoints in the main RESOLUTE All Comers trial. The principal OCT endpoint was tissue coverage, evaluated as the completeness of coverage (proportion of uncovered struts per stent) and as the mean thickness of coverage. Additional OCT endpoints included apposition and standard areas and volumes.

Optical coherence tomography analysis

Optical coherence tomography pullbacks were obtained at 13-month follow-up with M2, M3, or C7 systems (Lightlab Imaging, Westford, MA, USA), depending on the site, using an occlusive or a non-occlusive technique, as appropriate³³ (Table 1).

Optical coherence tomography pullbacks were analysed offline in a core laboratory (Cardialysis BV, Rotterdam, The Netherlands) by independent analysts blinded to stent-type allocation and clinical and procedural characteristics of the patients, using proprietary software (Lightlab Imaging). Cross-sections at 1 mm intervals within the stented segment and 5 mm proximal and distal to the stent edges were analysed. Lumen and stent areas were drawn in each analysed cross-section, and the derived incomplete stent apposition (ISA) or

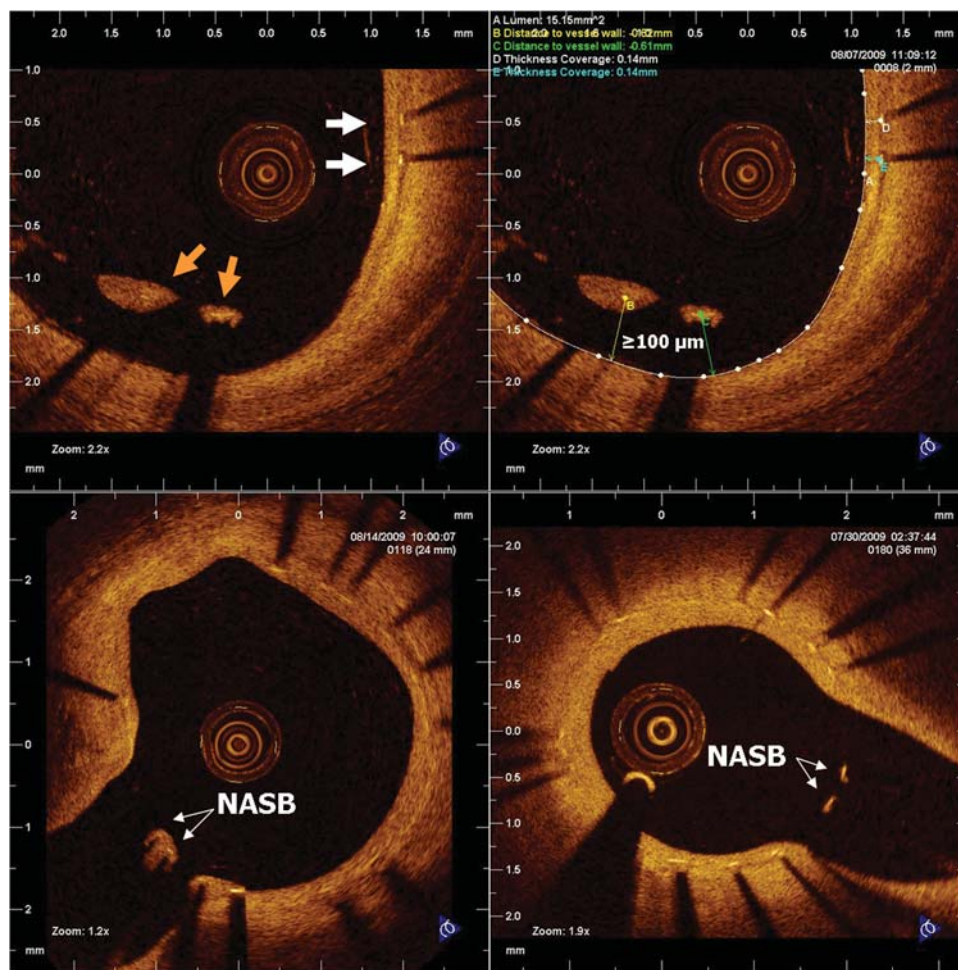


Figure 1 Categories of apposition. Optical coherence tomography cross-sections showing examples of struts in the three different categories of apposition: well-apposed (white arrows), incomplete stent apposition (orange arrows), and; NASB, non-apposed side branch.

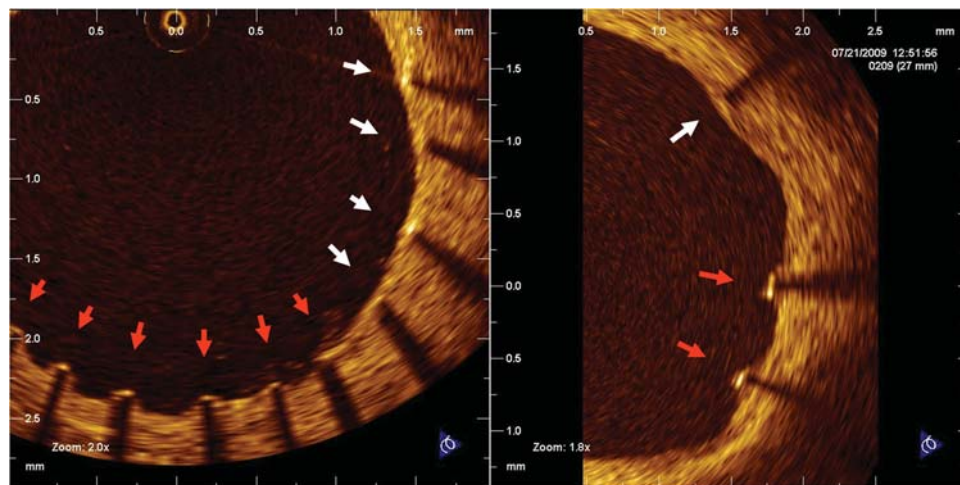


Figure 2 Coverage. Optical coherence tomography cross-sections showing examples of covered (white arrows) and non-covered struts (red arrows).

NIH areas were calculated as appropriate. A metallic strut typically appears as a bright signal-intense structure with dorsal shadowing. Apposition was assessed strut by strut by measuring the distance between the strut marker and the lumen contour. The marker of each strut was placed at the endoluminal leading edge, in the mid-point of its long axis, and the distance was measured following a straight line connecting this marker with the centre of gravity of the vessel³⁴ (Figure 1). Struts with distance to lumen contour larger than the sum of strut + polymer thickness were considered malapposed. This resulted in ISA thresholds of >97 μm for ZES and >89 μm for EES. Struts located at the ostium of side branches, with no vessel wall behind, were labelled as non-apposed side-branch (NASB) struts and excluded from the analysis of apposition (Figure 1).

Struts were classified as uncovered if any part of the strut was visibly exposed to the lumen, or covered if a layer of tissue was visible over all the reflecting surfaces. In covered struts, the thickness of coverage was measured from the strut marker to the endoluminal edge of the tissue coverage, following a straight line connecting the strut marker with the centre of gravity of the vessel (Figure 2).

To summarize the spatial distribution of the uncovered struts along the stents, 'spread-out-vessel graphics' were created by correlating the longitudinal distance from the distal edge of the stent to the strut (abscises) with the angle where the struts were located in the circular cross-section section respect to the centre of gravity of the vessel (ordinates). The resultant graphic represented the stented vessel, as if it had been cut longitudinally along the reference angle 0° and spread out on a flat surface (Figure 3).

Statistical analysis

Results are reported as mean \pm standard deviation for continuous variables and as count (%) for nominal variables. Continuous variables with normal distribution were compared with Student's *t*-test for independent samples or with the Mann–Whitney *U*-test in the case that normal distribution could not be assumed. Nominal variables were compared with Fisher's exact test.

In the per strut analysis, apposition was estimated through a categorical variable, comprising three possible excluding categories (well

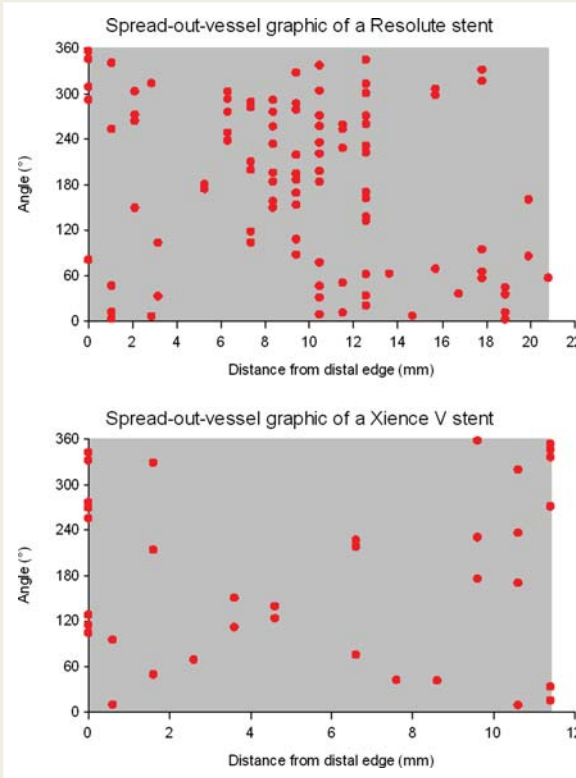


Figure 3 Spread-out-vessel graph, illustrative cases. The X-axis represents the distance from the distal edge of the stent to the strut; the Y-axis represents the angle where the strut is located in the circular cross-section with respect to the centre of gravity of the vessel. The result is a graphic representing the spatial distribution of the non-covered struts (red spots) along the stent, as if it had been cut along the reference angle (0°) and spread out on a flat surface.

apposed, ISA, or NASB). Tissue coverage was estimated through the proportion of uncovered struts (dichotomous variable) and through the mean thickness of coverage (continuous). Dichotomous or categorical variables were analysed using multilevel logistic regression models with random effects at four different levels: (i) treatment arm, (ii) patient, (iii) lesion, and (iv) stent. Likewise, continuous variables were analysed using multilevel linear regression models with random effects at the same four levels. Overlapping stents and

stents separated by a gap of <5 mm length within the same coronary segment were assigned to the same coronary lesion. Overlap segments were considered separate units of clustering at the stent level for the per strut multilevel analysis.

All statistical analyses were performed according to the intention-to-treat as specified in the protocol, using the SAS v8.2 package (SAS Institute Inc., Cary, NC, USA). All tests were two-sided and a *P*-value of <0.05 was considered statistically significant.

Table 2 Baseline patient characteristics

	ZES (n = 30)	EES (n = 28)	P-value
Age (years)	60.9 (12.5)	62.6 (8.9)	0.547
Males	23 (76.7%)	23 (82.1%)	0.749
BMI (kg/m ²)	83.7 (18.4)	28.8 (4.8)	0.476
Cardiovascular risk factors			
Hypertension	18 (60.0%)	15 (53.6%)	0.791
DM	7 (23.3%)	7 (25%)	1.000
Insulin-requiring	0 (0.0%)	2 (7.1%)	0.229
Hypercholesterolaemia	21 (70.0%)	20 (71.4%)	1.000
Smoking	18 (60.0%)	16 (57.1%)	1.000
Current smoker (<30 days)	11 (36.7%)	9 (32.1%)	0.787
Family history of CHD	7 (35.0%)	11 (50.0%)	0.366
Antecedents			
Previous MI	7 (25.0%)	9 (32.1%)	0.768
Previous PCI	8 (26.7%)	4 (14.3%)	0.336
With BMS	1 (3.3%)	3 (10.7%)	0.344
With DES	5 (16.7%)	1 (3.6%)	0.195
Previous CABG	2 (6.7%)	3 (10.7%)	0.665
Clinical presentation			
Stable angina	16 (53.3%)	11 (39.3%)	0.306
Unstable angina	3 (10.0%)	5 (17.9%)	0.464
Myocardial infarction	9 (30%)	10 (35.7%)	0.781
STEMI	6 (20.0%)	7 (25.0%)	0.757
Silent ischaemia	2 (6.7%)	2 (7.1%)	1.000
Serum creatinine (μmol/L)	76.2 (18.1)	87.4 (23.6)	0.048*
Ejection fraction (%)	65 (10)	55 (11)	0.041*
Angiographic characteristics			
No. of diseased major vessels			
One	22 (73.3%)	22 (78.6%)	0.762
Two	7 (23.3%)	6 (21.4%)	1.000
Three	1 (3.3%)	0 (0.0%)	1.000
LM + 3 vessels	0 (0.0%)	0 (0.0%)	NA
Syntax score	14.13 (12.19)	14.19 (9.10)	0.984

Data presented as no. of events (%) or mean (SD), as appropriate. BMI, body mass index; BMS, bare-metal stent; CABG, coronary artery bypass graft; CHD, coronary heart disease; DES, drug-eluting stent; DM, diabetes mellitus; EES, everolimus-eluting stent; LM, left main stem; MI, myocardial infarction; PCI, percutaneous coronary intervention; STEMI, ST elevation myocardial infarction; ZES, zotarolimus-eluting stent.

**P* ≤ 0.05.

Results

Two thousand two hundred and ninety-two patients were enrolled in the RESOLUTE All Comers trial. Fifty-eight patients (30 ZES and 28 EES) with 107 stents in 72 lesions underwent OCT at 13 months. Nine out of 2718 (0.33%) cross-sections were deemed of insufficient quality for the quantitative analysis. In total, 23 197 struts were analysed. Tables 2–4 show the baseline characteristics of patients, procedures, and lesions, respectively, in both treatment arms. The randomization produced comparable groups, except patients who received EES had significantly higher serum levels of creatinine and lower left ventricular

Table 3 Procedural characteristics (per patient)

	ZES (n = 30)	EES (n = 28)	P-value
Contrast (ml)	264.0 (148.6)	265.8 (125.4)	0.962
Procedure duration (min)	59.1 (40.3)	56.7 (41.8)	0.826
No. of vessels treated	1.30 (0.54)	1.21 (0.42)	0.501
LAD	15 (50.0%)	13 (46.4%)	0.799
LCX	8 (26.7%)	9 (32.1%)	0.775
RCA	15 (50.0%)	11 (39.3%)	0.441
LM	1 (3.3%)	1 (3.6%)	1.000
No. of lesions treated	1.4 (0.7)	1.5 (0.6)	0.711
No. of stents implanted	2.0 (1.8)	2.4 (1.2)	0.381
Total stented length (mm)	40.1 (42.6)	47.9 (29.7)	0.428
Cross-over	0 (0.0%)	0 (0.0%)	NA
On-label use	13 (43.3%)	10 (35.7%)	0.600
Long lesion (>27 mm) ^a	3 (12.0%)	3 (13.6%)	1.000
Small vessel (<2.5 mm diameter) ^a	12 (48.0%)	15 (68.2%)	0.238
Anti-platelet therapy			
Dual at 6 months	28 (93.3%)	27 (96.4%)	1.000
Dual at 12 months	27 (90.0%)	26 (92.9%)	1.000
Aspirin at 12 months	28 (93.3%)	27 (96.4%)	1.000
Clopidogrel at 12 months	29 (96.7%)	27 (96.4%)	1.000

Data presented as no. of events (%) or mean (SD), as appropriate. EES, everolimus-eluting stent; LAD, left anterior descending; LCX, left circumflex; LM, left main stem; RCA, right coronary artery; ZES, zotarolimus-eluting stent.

^aDerived from QCA data.

Table 4 Lesions characteristics

	ZES (n = 36)	EES (n = 36)	P-value
Target vessel			
LM	0 (0.0%)	1 (2.8%)	1.000
LAD	14 (38.9%)	15 (41.7%)	1.000
LCX	5 (13.9%)	6 (16.7%)	1.000
RCA	17 (47.2%)	14 (38.9%)	0.634
Pre-procedural TIMI flow			
0	6 (16.7%)	6 (16.7%)	1.000
I	1 (2.8%)	2 (5.6%)	1.000
II	3 (8.3%)	2 (5.6%)	1.000
III	26 (72.2%)	26 (72.2%)	1.000
Post-procedural TIMI flow			
II	1 (2.8%)	0 (0.0%)	1.000
III	35 (97.2%)	36 (100.0%)	1.000
TO	6 (16.7%)	6 (16.7%)	1.000
Ostial lesion	1 (2.8%)	1 (2.8%)	1.000
Bifurcation	8 (22.2%)	12 (33.3%)	0.430
Moderate or severe calcification	8 (22.2%)	5 (13.9%)	0.541
Angiographic edge dissections	1 (2.8%)	0 (0.0%)	1.000
Complications	0 (0.0%)	0 (0.0%)	NA
QCA characteristics			
Lesion length (mm)	16.6 (9.9)	13.8 (10.0)	0.297
Pre-stenting			
RVD (mm)	2.84 (0.56)	2.59 (0.54)	0.089
MLD (mm)	0.88 (0.58)	0.78 (0.51)	0.438
% diam stenosis	69 (19)	70 (19)	0.942
Post-stenting			
In-stent			
RVD (mm)	2.91 (0.49)	2.82 (0.45)	0.401
MLD (mm)	2.44 (0.51)	2.40 (0.48)	0.717
% diam stenosis	16 (8)	15 (7)	0.476
In-segment			
RVD (mm)	2.83 (0.47)	2.66 (0.46)	0.116
MLD (mm)	2.15 (0.44)	2.01 (0.39)	0.161
% diam stenosis	24 (9)	24 (9)	0.923

Data presented as no. of events (%) or mean (SD), as appropriate. EES, everolimus-eluting stent; LAD, left anterior descending; LCX, left circumflex; LM, left main stem; MLD, minimal lumen diameter; QCA, quantitative coronary angiography; RCA, right coronary artery; RVD, reference vessel diameter; TO, total occlusion; ZES, zotarolimus-eluting stent. Lesion length and RVD were not available for 17 lesions due to initial TIMI flow 0/I; for one lesion in the ZES group, the pre-stenting lesion length, RVD, MLD, and % diameter stenosis could not be determined due to overlapping vessels.

* $P \leq 0.05$.

ejection fraction than those who received ZES. No clinical events were observed in the patients in the OCT substudy, except for a non-Q-wave myocardial infarction in the EES group. No patient was excluded from the study on the basis of clinical outcomes.

Table 5 Areas and volumetric analysis per stent (excluding overlapping segments) at 13-month follow-up

	ZES: 30 patients, 36 lesions, 50 stents	EES: 28 patients, 36 lesions, 57 stents	P-value
58 patients, 72 lesions, 107 stents			
Stent length (mm)	18.7 (9.3)	18.6 (8.6)	0.959
MLA (mm ²)	5.45 (2.39)	5.35 (2.45)	0.845
Mean lumen area (mm ²)	6.89 (2.52)	6.68 (2.75)	0.681
Lumen volume (mm ³)	130.1 (80.4)	123.2 (73.0)	0.641
Min stent area (mm ²)	6.37 (2.41)	6.47 (2.42)	0.831
Mean stent area (mm ²)	7.70 (2.38)	7.64 (2.59)	0.902
Stent volume (mm ³)	145.2 (85.1)	140.8 (77.2)	0.777
% frames with ISA	5.10 (9.84)	3.18 (7.00)	0.255
Max ISA area (mm ²)	0.39 (0.76)	0.49 (1.56)	0.666
ISA volume (mm ³)	0.79 (1.80)	1.08 (3.90)	0.615
ISA volume (% of stent volume)	0.58 (1.39)	0.66 (2.27)	0.835
Max NIH area (mm ²)	1.73 (0.82)	1.88 (0.87)	0.367
NIH volume (mm ³)	15.9 (11.6)	18.7 (14.4)	0.274
NIH volume obstruction (%)	12.5 (7.9)	15.0 (10.7)	0.157

Data presented as mean (SD). EES, everolimus-eluting stent; ISA, incomplete stent apposition; MLA, minimal lumen area; NIH, neointimal hyperplasia; ZES, zotarolimus-eluting stent.

Table 6 Areas and volumetric analysis of overlapping segments at 13-month follow-up

	ZES: 8 patients, 9 lesions, 11 overlaps	EES: 11 patients, 12 lesions, 17 overlaps	P-value
19 patients, 21 lesions, 28 overlaps			
Overlap length (mm)	2.4 (2.4)	2.1 (2.7)	0.771
MLA (mm ²)	5.37 (2.09)	6.67 (2.89)	0.208
Mean lumen Area (mm ²)	5.61 (2.14)	6.93 (2.97)	0.213
Lumen volume (mm ³)	14.1 (16.2)	16.1 (22.8)	0.805
Min stent area (mm ²)	6.15 (1.70)	7.89 (3.02)	0.095
Mean stent area (mm ²)	6.50 (1.68)	8.20 (3.00)	0.100
Stent volume (mm ³)	15.7 (17.3)	18.5 (26.2)	0.760
% frames with ISA	3.03 (10.05)	2.94 (12.13)	0.984
Max ISA area (mm ²)	0.02 (0.08)	0.02 (0.07)	0.821
ISA volume (mm ³)	0.01 (0.04)	0.01 (0.04)	0.892
ISA volume (% of stent volume)	0.10 (0.34)	0.24 (0.99)	0.601
Max NIH area (mm ²)	1.16 (0.56)	1.50 (0.94)	0.297
NIH volume (mm ³)	1.7 (1.5)	2.5 (3.6)	0.433
NIH volume obstruction (%)	16.0 (12.3)	17.0 (11.8)	0.835

Data presented as mean (SD). EES, everolimus-eluting stent; ISA, incomplete stent apposition; MLA, minimal lumen area; NIH, neointimal hyperplasia; ZES, zotarolimus-eluting stent.

Table 7 Analysis of apposition and coverage per strut at 13-month follow-up

All struts: 58 patients, 72 lesions, 107 stents, 23 197 struts	ZES: 30 patients, 36 lesions, 50 stents, 11 930 struts	EES: 28 patients, 36 lesions, 57 stents, 11 267 struts		Estimate	95% CI		P-value
					Low	Up	
Apposition							
Apposition category							
Well-apposed	11 624 (97.4%)	10 989 (97.5%)	OR	0.96	0.52	1.76	0.898
ISA	216 (1.8%)	161 (1.4%)	OR	1.27	0.56	2.91	0.569
NASB	90 (0.8%)	117 (1.0%)	OR	0.72	0.41	1.29	0.271
Coverage							
Thickness of coverage (µm)	116 (99)	142 (113)	Difference	-11.4	-42.4	19.65	0.466
Coverage category							
Covered	11 043 (92.6%)	10 613 (94.2%)	OR	0.77	0.43	1.38	0.378
Uncovered	887 (7.4%)	654 (5.8%)	OR	1.30	0.72	2.33	
Overlapping segments:							
8 patients, 19 patients, 21 lesions, 28 overlaps, 1251 struts	8 patients, 9 lesions, 11 overlaps, 629 struts	11 patients, 12 lesions, 17 overlaps, 622 struts					
Apposition							
Apposition category							
Well-apposed	626 (99.5%)	618 (99.4%)	OR	1.35	0.14	13.50	0.798
ISA	3 (0.5%)	1 (0.2%)	OR	2.98	0.19	47.83	0.441
NASB	0 (0.0%)	3 (0.5%)	OR	—	—	—	NA
Coverage							
Thickness of coverage (µm)	129 (98)	171 (125)	Difference	-47.97	-159.37	63.44	0.376
Coverage category							
Covered	588 (93.5%)	600 (96.5%)	OR	0.53	0.24	1.16	0.111
Uncovered	41 (6.5%)	22 (3.5%)	OR	1.89	0.86	4.17	

EES, everolimus-eluting stent; ISA, incomplete stent apposition; NASB, non-apposed side branch; ZES, zotarolimus-eluting stent.

Tables 5 and 6 show mean in-stent areas and volumes in non-overlapping and overlapping segments, respectively, without significant differences between both stent types. Table 7 shows the comparative results of the variables estimating apposition and tissue coverage. There were no significant differences in the proportion of non-covered struts or in the mean thickness of coverage between the treatment groups in multilevel analysis. Introducing the variables with imbalanced distribution (serum creatinine and ejection fraction) in the regression model as covariates did not translate into any significant variation in the differences in coverage.

Figure 4 shows the spread-out-vessel graphics of the 109 stents and corresponding overlaps.

Discussion

The main finding of this study is that OCT did not detect any significant difference between ZES and EES in tissue coverage

at 13 months. Both DES have durable polymers, but with different properties. The BioLinx polymer on ZES is an amphiphilic blend of three different polymers, with a hydrophilic surface in contact with the blood or the vessel wall. Conversely, the poly(vinylidene fluoride-co-hexafluoropropylene) on EES offers a hydrophobic fluorinated surface that might induce fluoropassivation. Hydrophilicity (ZES) and fluoropassivation (EES) improve both the biocompatibility of the corresponding intracoronary device, as discussed previously. No significant differences were found in the mean thickness of coverage, although it tended to be thinner in ZES. Likewise, there were no significant differences regarding the proportion of covered struts, a possible surrogate for the completeness of neointimal coverage. In view of these results, a hydrophilic polymer coating does not seem to translate into any clear advantage in terms of neointimal coverage with respect to a hydrophobic fluoropolymer coating. Beyond the hydrophilicity of the polymer surface, other factors such as the different antiproliferative drugs (with different inhibitory




Figure 4 Spread-out-vessel graphics showing non-covered struts of the 109 stents and corresponding overlaps analysed at 13 months. The graphic summarizes the spatial distribution of non-coverage and its clustering at the four considered levels (allocation to treatment, patient, lesion, and stent).

potency and dose), the kinetics of release (more sustained release in ZES, prolonged up to 180 days), mechanical characteristics of the stent platform, and the polymer itself play certainly a role in determining the neointimal coverage after stenting. Interestingly, the proportion of uncovered struts in ZES in our study is higher than in previous OCT studies on another ZES with a phosphorylcholine polymer and different kinetics of release.^{18,35} This could be the consequence of the sustained drug elution, although the absolute proportions in these studies cannot be directly compared due to small methodological differences in the assessment.

Since no significant differences in ISA were found between the treatment groups, an eventual confounding effect of ISA on the coverage can be ruled out.

Because the number of patients in the OCT substudy was modest compared with the large numbers in the main trial, and a sizeable number of control variables were tested, some differences appeared by chance between treatment groups in spite of randomization. In order to control potential confusion, an additional sensitivity analysis was performed, introducing the variables with imbalanced distribution as covariates in the multilevel regression models, but the results did not change with respect to the pre-specified analysis.

The results about OCT coverage seem consistent with the clinical findings of the RESOLUTE All Comers trial,³¹ in which ZES proved to be non-inferior to EES for target-lesion failure. Furthermore, on the basis of this OCT substudy, differences in coverage cannot be advocated to explain the ambiguous clinical results regarding stent thrombosis. The correlation between OCT substudies and the clinical outcome of large prospective trials can contribute to understand the predictive value of OCT. In the LEADERS trial, the OCT substudy detected an advantage in coverage in one of the stents at 9 months,¹⁶ but no differences in thrombosis rates have been reported hitherto.²⁰ Likewise, HORIZONS-AMI found worse coverage in DES than in BMS after primary PCI,³⁶ but no significant difference in thrombosis.³⁷ In RESOLUTE All Comers, there was a non-significant trend to lower stent thrombosis in the EES group, although most of the events occurred in the first 30 days when neointimal healing is still unlikely to play a role.³¹ The results of this OCT substudy could be interpreted as reassuring that factors other than differences in coverage are the key for these clinical results, but the potential of OCT coverage to predict future thrombotic events must be still properly understood.

The 'spread-out-vessel' summary in *Figure 4* may be the best possible graphic representation for the clustering and spatial distribution of non-coverage. It clearly shows, without the need of complex statistics, that the type of stent is not the only factor determining coverage: concentration of uncovered struts in some patients or in some stents within a patient or in some regions within a stent points out clearly the relevance of individual, mechanical, and loco-regional factors, respectively. Among them, diabetes,³⁸ levels of circulating endothelial progenitor cells,³⁹ or regional shear stress^{40,41} are known to play a role in neointimal healing after stenting.

Limitations

The unequal distribution of some control variables in the randomization has been previously addressed.

Some caution should be advised about using OCT tissue coverage as a surrogate of neointimal healing. Although biologically plausible and intuitively accepted by the scientific community, this approach cannot be fully supported by current evidence. Optical coherence tomography tissue coverage correlates with histological neointimal healing and endothelialization after stenting in animal models,^{12–14} but its sensitivity and specificity in human atherosclerotic vessels are still unknown. Optical coherence tomography is not able to detect thin layers of the endothelium, below its 10–20 μm axial resolution, and cannot discern between neointima and other material, such as fibrin or thrombus. The analysis of

optical density might be useful in the future to discern between neointima and fibrin.¹⁵

Per strut quantitative analysis was performed at 1 mm longitudinal intervals. Although this methodology has been experimentally validated for the assessment of coverage¹⁴ and showed excellent reproducibility,³⁴ it might have different sensitivity to detect uncovered struts than shorter longitudinal intervals. The results from studies using different longitudinal segmentation might not be directly comparable.

Finally, the OCT substudy of RESOLUTE All Comers did not follow a non-inferiority design, as was done in the main trial. Therefore, the conclusion cannot be the absence of significant differences between the compared stents, in spite of not having found them. The possibility of an underpowered design cannot be strictly ruled out, although the lack of any clear trend between the groups makes it very unlikely.

Conclusion

No significant differences in tissue coverage, malapposition, or lumen/stent areas and volumes were detected by OCT between the hydrophilic polymer-coated ZES and the fluoropolymer-coated EES at 13-month follow-up.

Acknowledgements

Dick Goedhart (senior statistician), Peter Jüni (Institute of Social and Preventive Medicine, University of Bern, CH), and Gerritt-Anne van Es (Cardialysis BV, Rotterdam, The Netherlands) for their scientific advice.

Funding

The study was supported by Medtronic Inc., Santa Rosa, CA, USA. Funding to pay the Open Access publication charges for this article was provided by Medtronic Inc., Santa Rosa, CA, USA.

Conflict of interest: This study has been sponsored by Medtronic Inc., Santa Rosa, CA, USA. The core-lab and CRO responsible for the analysis (Cardialysis BV, Rotterdam, The Netherlands) and the participating centres (except Institute of Social and Preventive Medicine, University of Bern, Bern, Switzerland) have received grants from the sponsor to run the trial. P.W.S., S.W., and S.S. have received speakers' fees from the sponsor.

References

- Garg S, Serruys PW. Coronary stents: current status. *J Am Coll Cardiol* 2010;**56**: S1–S42.
- Iakovou I, Schmidt T, Bonizzoni E, Ge L, Sangiorgi GM, Stankovic G, Airoldi F, Chieffo A, Montorfano M, Carlino M, Michev I, Corvaja N, Briguori C, Gerckens U, Grube E, Colombo A. Incidence, predictors, and outcome of thrombosis after successful implantation of drug-eluting stents. *JAMA* 2005;**293**: 2126–2130.
- Ong AT, McFadden EP, Regar E, de Jaegere PP, van Domburg RT, Serruys PW. Late angiographic stent thrombosis (LAST) events with drug-eluting stents. *J Am Coll Cardiol* 2005;**45**:2088–2092.
- Pfisterer M, Brunner-La Rocca HP, Buser PT, Rickenbacher P, Hunziker P, Mueller C, Jeger R, Bader F, Osswald S, Kaiser C. Late clinical events after clopidogrel discontinuation may limit the benefit of drug-eluting stents: an observational study of drug-eluting versus bare-metal stents. *J Am Coll Cardiol* 2006;**48**: 2584–2591.
- Lagerqvist B, James SK, Stenestrand U, Lindback J, Nilsson T, Wallentin L, the SCAAR Study Group. Long-term outcomes with drug-eluting stents versus bare-metal stents in Sweden. *N Engl J Med* 2007;**356**:1009–1019.
- Farb A, Heller PF, Shroff S, Cheng L, Kolodgie FD, Carter AJ, Scott DS, Froehlich J, Virmani R. Pathological analysis of local delivery of paclitaxel via a polymer-coated stent. *Circulation* 2001;**104**:473–479.
- Farb AM, Burke APM, Kolodgie FDP, Virmani RM. Pathological mechanisms of fatal late coronary stent thrombosis in humans. *Circulation* 2003;**108**:1701–1706.
- Joner M, Finn AV, Farb A, Mont EK, Kolodgie FD, Ladich E, Kutys R, Skorija K, Gold HK, Virmani R. Pathology of drug-eluting stents in humans: delayed healing and late thrombotic risk. *J Am Coll Cardiol* 2006;**48**:193–202.
- Finn AV, Joner M, Nakazawa G, Kolodgie F, Newell J, John MC, Gold HK, Virmani R. Pathological correlates of late drug-eluting stent thrombosis: strut coverage as a marker of endothelialization. *Circulation* 2007;**115**:2435–2441.
- Virmani R, Guagliumi G, Farb A, Musumeci G, Grieco N, Motta T, Mihalskik L, Tespili M, Valsecchi O, Kolodgie FD. Localized hypersensitivity and late coronary thrombosis secondary to a sirolimus-eluting stent: should we be cautious? *Circulation* 2004;**109**:701–705.
- Duckers HJ, Soullie T, den Heijer P, Rensing B, de Winter RJ, Rau M, Mudra H, Silber S, Benit E, Verheye S, Wijns W, Serruys PW. Accelerated vascular repair following percutaneous coronary intervention by capture of endothelial progenitor cells promotes regression of neointimal growth at long term follow-up: final results of the Healing II trial using an endothelial progenitor cell capturing stent (Genous R stent). *EuroIntervention* 2007;**3**:350–358.
- Suzuki Y, Ikeno F, Koizumi T, Tio F, Yeung AC, Yock PG, Fitzgerald PJ, Fearon WF. In vivo comparison between optical coherence tomography and intravascular ultrasound for detecting small degrees of in-stent neointima after stent implantation. *JACC Cardiovasc Interv* 2008;**1**:168–173.
- Prati F, Zimarino M, Stabile E, Pizzicannella G, Fouad T, Rabozzi R, Filippini A, Pizzicannella J, Cera M, De Caterina R. Does optical coherence tomography identify arterial healing after stenting? An in vivo comparison with histology, in a rabbit carotid model. *Heart* 2008;**94**:217–221.
- Murata A, Wallace-Bradley D, Tellez A, Alviar C, Aboodi M, Sheehy A, Coleman L, Perkins L, Nakazawa G, Mintz G, Kaluza GL, Virmani R, Granada JF. Accuracy of optical coherence tomography in the evaluation of neointimal coverage after stent implantation. *JACC Cardiovasc Imaging* 2010;**3**:76–84.
- Templin C, Meyer M, Muller MF, Djonov V, Hlushchuk R, Dimova I, Flueckiger S, Kronen P, Sidler M, Klein K, Nicholls F, Ghadri JR, Weber K, Paunovic D, Corti R, Hoerstrup SP, Luscher TF, Landmesser U. Coronary optical frequency domain imaging (OFDI) for in vivo evaluation of stent healing: comparison with light and electron microscopy. *Eur Heart J* 2010;**31**:1792–1801.
- Barlis P, Regar E, Serruys PW, Dimopoulos K, van der Giessen WJ, van Geuns RJ, Ferrante G, Wandel S, Windecker S, Van Es GA, Eerdman P, Juni P, di Mario C. An optical coherence tomography study of a biodegradable vs. durable polymer-coated limus-eluting stent: a LEADERS trial sub-study. *Eur Heart J* 2010;**31**: 165–176.
- Guagliumi G, Sirbu V, Musumeci G, Bezerra HG, Aprile A, Kyono H, Fiocca L, Matiashvili A, Lortkipanidze N, Vassileva A, Popma JJ, Alocco DJ, Dawkins KD, Valsecchi O, Costa MA. Strut coverage and vessel wall response to a new-generation paclitaxel-eluting stent with an ultrathin biodegradable abluminal polymer: Optical Coherence Tomography Drug-Eluting Stent Investigation (OCTDES). *Circ Cardiovasc Interv* 2010;**3**:367–375.
- Guagliumi G, Sirbu V, Bezerra H, Biondi-Zoccai G, Fiocca L, Musumeci G, Matiashvili A, Lortkipanidze N, Tahara S, Valsecchi O, Costa M. Strut coverage and vessel wall response to zotarolimus-eluting and bare-metal stents implanted in patients with ST-segment elevation myocardial infarction: the OCTAMI (Optical Coherence Tomography in Acute Myocardial Infarction) Study. *JACC Cardiovasc Interv* 2010;**3**:680–687.
- Cook S, Ladich E, Nakazawa G, Eshetehardi P, Neidhart M, Vogel R, Togni M, Wenaweser P, Billinger M, Seiler C, Gay S, Meier B, Pichler WJ, Juni P, Virmani R, Windecker S. Correlation of intravascular ultrasound findings with histopathological analysis of thrombus aspirates in patients with very late drug-eluting stent thrombosis. *Circulation* 2009;**120**:391–399.
- Windecker S, Serruys PW, Wandel S, Buszman P, Trznadel S, Linke A, Lenk K, Ischinger T, Klaus V, Eberli F, Corti R, Wijns W, Morice MC, Di MC, Davies S, van Geuns RJ, Eerdman P, Van Es GA, Meier B, Juni P. Biolimus-eluting stent with biodegradable polymer versus sirolimus-eluting stent with durable polymer for coronary revascularisation (LEADERS): a randomised non-inferiority trial. *Lancet* 2008;**372**:1163–1173.
- Udipi K, Melder RJ, Chen M, Cheng P, Hezi-Yamit A, Sullivan C, Wong J, Wilcox J. The next generation Endeavor Resolute Stent: role of the BioLinx Polymer System. *EuroIntervention* 2007;**3**:137–139.
- Udipi K, Chen M, Cheng P, Jiang K, Judd D, Caceres A, Melder RJ, Wilcox JN. Development of a novel biocompatible polymer system for extended drug release in a next-generation drug-eluting stent. *J Biomed Mater Res A* 2008;**85**: 1064–1071.

23. Hezi-Yamit A, Sullivan C, Wong J, David L, Chen M, Cheng P, Shumaker D, Wilcox JN, Udipi K. Impact of polymer hydrophilicity on biocompatibility: implication for DES polymer design. *J Biomed Mater Res A* 2009;**90**:133–141.
24. Rogers C, Welt FG, Karnovsky MJ, Edelman ER. Monocyte recruitment and neointimal hyperplasia in rabbits. Coupled inhibitory effects of heparin. *Arterioscler Thromb Vasc Biol* 1996;**16**:1312–1318.
25. Carter AJ, Melder RJ, Udipi K, Ozdil F, Virmani R, Wilcox J. In vivo performance of a novel co-polymer system for extended release of zotarolimus in a next generation drug-eluting stent. Presented at the *Transcatheter Cardiovascular Therapeutics Annual Meeting*, Washington, DC. 2006. Ref Type: Abstract.
26. Guidoin R, Marois Y, Zhang Z, King M, Martin L, Laroche G, Awad J. The benefits of fluoropassivation of polyester arterial prostheses as observed in a canine model. *ASAIO J* 1994;**40**:M870–M879.
27. Xie X, Guidoin R, Nutley M, Zhang Z. Fluoropassivation and gelatin sealing of polyester arterial prostheses to skip preclotting and constrain the chronic inflammatory response. *J Biomed Mater Res B Appl Biomater* 2010;**93**:497–509.
28. Meredith IT, Worthley S, Whitbourn R, Walters D, Popma J, Cutlip D, Fitzgerald P. The next-generation Endeavor Resolute stent: 4-month clinical and angiographic results from the Endeavor Resolute first-in-man trial. *EuroIntervention* 2007;**3**:50–53.
29. Meredith IT, Worthley S, Whitbourn R, Walters DL, McClean D, Horrigan M, Popma JJ, Cutlip DE, DePaoli A, Negoita M, Fitzgerald PJ. Clinical and angiographic results with the next-generation resolute stent system: a prospective, multicenter, first-in-human trial. *JACC Cardiovasc Interv* 2009;**2**:977–985.
30. Meredith IT, Worthley S, Whitbourn R, Walters D, McClean D, Ormiston J, Horrigan M, Wilkins GT, Hendriks R, Matsis P, Muller D, Cutlip D. Long-term clinical outcomes with the next-generation Resolute Stent System: a report of the two-year follow-up from the RESOLUTE clinical trial. *EuroIntervention* 2010;**5**:692–697.
31. Serruys PW, Silber S, Garg S, van Geuns RJ, Richardt G, Buszman PE, Kelbaek H, van Boven AJ, Hofma SH, Linke A, Klauss V, Wijns W, Macaya C, Garot P, DiMario C, Manoharan G, Kornowski R, Ischinger T, Bartorelli A, Ronden J, Bressers M, Gobbens P, Negoita M, van Leeuwen F, Windecker S. Comparison of zotarolimus-eluting and everolimus-eluting coronary stents. *N Engl J Med* 2010;**363**:136–146.
32. Ruygrok PN, Desaga M, Van Den BF, Rasmussen K, Suryapranata H, Dorange C, Veldhof S, Serruys PW. One year clinical follow-up of the XIENCE V Everolimus-eluting stent system in the treatment of patients with de novo native coronary artery lesions: the SPIRIT II study. *EuroIntervention* 2007;**3**:315–320.
33. Gonzalo N, Tearney GJ, Serruys PW, van Soest G, Okamura T, Garcia-Garcia HM, van Geuns RJ, van der Ent M, Ligthart JM, Bouma BE, Regar E. Second-generation optical coherence tomography in clinical practice. High-speed data acquisition is highly reproducible in patients undergoing percutaneous coronary intervention. *Rev Esp Cardiol* 2010;**63**:893–903.
34. Gonzalo N, Garcia-Garcia HM, Serruys PW, Commissaris KH, Bezerra H, Gobbens P, Costa M, Regar E. Reproducibility of quantitative optical coherence tomography for stent analysis. *EuroIntervention* 2009;**5**:224–232.
35. Guagliumi G, Musumeci G, Sirbu V, Bezerra HG, Suzuki N, Fiocca L, Matiashvili A, Lortkipanidze N, Trivisonno A, Valsecchi O, Biondi-Zoccai G, Costa MA. Optical coherence tomography assessment of in vivo vascular response after implantation of overlapping bare-metal and drug-eluting stents. *JACC Cardiovasc Interv* 2010;**3**:531–539.
36. Guagliumi G, Costa MA, Sirbu V, Musumeci G, Bezerra HG, Suzuki N, Matiashvili A, Lortkipanidze N, Mihalcsik L, Trivisonno A, Valsecchi O, Mintz GS, Dressler O, Parise H, Maehara A, Cristea E, Lansky AJ, Mehran R, Stone GW. Strut coverage and late malapposition with paclitaxel-eluting stents compared with bare metal stents in acute myocardial infarction: optical coherence tomography substudy of the Harmonizing Outcomes With Revascularization and Stents in Acute Myocardial Infarction (HORIZONS-AMI) Trial. *Circulation* 2011;**123**:274–281.
37. Stone GW, Lansky AJ, Pocock SJ, Gersh BJ, Dangas G, Wong SC, Witztzenbichler B, Guagliumi G, Peruga JZ, Brodie BR, Dudek D, Möckel M, Ochala A, Kellock A, Parise H, Mehran R. Paclitaxel-eluting stents versus bare-metal stents in acute myocardial infarction. *N Engl J Med* 2009;**360**:1946–1959.
38. Tanaka N, Terashima M, Rathore S, Itoh T, Habara M, Nasu K, Kimura M, Itoh T, Kinoshita Y, Ehara M, Tsuchikane E, Asakura K, Asakura Y, Katoh O, Suzuki T. Different patterns of vascular response between patients with or without diabetes mellitus after drug-eluting stent implantation: optical coherence tomographic analysis. *JACC Cardiovasc Interv* 2010;**3**:1074–1079.
39. Duckers HJ, Silber S, de Winter R, den Heijer P, Rensing B, Rau M, Mudra H, Benit E, Verheye S, Wijns W, Serruys PW. Circulating endothelial progenitor cells predict angiographic and intravascular ultrasound outcome following percutaneous coronary interventions in the HEALING-II trial: evaluation of an endothelial progenitor cell capturing stent. *EuroIntervention* 2007;**3**:67–75.
40. Wentzel JJ, Krams R, Schuurbiers JC, Oomen JA, Kloet J, van der Giessen WJ, Serruys PW, Slager CJ. Relationship between neointimal thickness and shear stress after Wallstent implantation in human coronary arteries. *Circulation* 2001;**103**:1740–1745.
41. Gijsen FJH, Oortman RM, Wentzel JJ, Schuurbiers JCH, Tanabe K, Degertekin M, Ligthart JM, Thury A, de Feyter PJ, Serruys PW, Slager CJ. Usefulness of shear stress pattern in predicting neointima distribution in sirolimus-eluting stents in coronary arteries. *Am J Cardiol* 2003;**92**:1325–1328.