

Rotational Atherectomy Does Not Reduce Recurrent In-Stent Restenosis

Results of the Angioplasty Versus Rotational Atherectomy for Treatment of Diffuse In-Stent Restenosis Trial (ARTIST)

Juergen vom Dahl, MD; Ulrich Dietz, MD; Philipp K. Haager, MD; Sigmund Silber, MD; Luigi Niccoli, MD; Hans Juergen Buettner, MD; Francois Schiele, MD; Martyn Thomas, MD; Philippe Commeau, MD; David R. Ramsdale, MD; Eulogio Garcia, MD; Christian W. Hamm, MD; Rainer Hoffmann, MD; Thorsten Reineke, Dipl Math; Heinrich G. Klues, MD;
for the ARTIST Investigators

Background—Aim of this trial was to compare rotational atherectomy followed by balloon angioplasty (rotablation [ROTA] group) with balloon angioplasty (percutaneous transluminal coronary angioplasty [PTCA] group) alone in patients with diffuse in-stent restenosis.

Methods and Results—The ARTIST study is a multicenter, randomized, prospective European trial with 298 patients with in-stent restenosis >70% (mean lesion length, 14 ± 8 mm) in stents, implanted in coronary arteries for ≥ 3 months. In the PTCA group, angioplasty was performed at the discretion of the local investigator, and rotablation was performed by using a stepped-burr approach followed by adjunctive PTCA with low (≤ 6 atm) inflation pressure. Intravascular ultrasound during the intervention and at follow-up was used in a substudy in 86 patients (45 PTCA, 41 ROTA). Angiography demonstrated no difference regarding the short-term outcome, with equivalent procedural success rates defined as remaining stenosis <30% (89% PTCA, 88% ROTA). However, the results showed that, in the long term, PTCA was a significantly better strategy than ROTA. Mean net gain in minimal lumen diameter was 0.67 mm and 0.45 mm for PTCA and ROTA, respectively ($P=0.0019$). Mean gain in diameter stenosis was 25% and 17% ($P=0.002$), resulting in restenosis ($\geq 50\%$) rates of 51% (PTCA) and 65% (ROTA) ($P=0.039$). By intravascular ultrasound, the major difference was the missing stent over-expansion during PTCA after ROTA. Six-month event-free survival was significantly higher after PTCA (91.3%) compared with ROTA (79.6%, $P=0.0052$).

Conclusions—In terms of the primary objective of the study, PTCA produced a significantly better long-term outcome than ROTA followed by adjunctive low-pressure PTCA. (*Circulation*. 2002;105:583-588.)

Key Words: angioplasty ■ stents ■ restenosis ■ rotational atherectomy ■ ultrasonics

Coronary in-stent restenosis (ISR) remains a significant clinical problem for interventional cardiologists.¹ In contrast to restenosis after balloon angioplasty (percutaneous transluminal coronary angioplasty, PTCA), ISR is almost exclusively attributable to neointimal hyperplasia, which may require different treatment strategies. Repeat PTCA remains the most commonly used technique for ISR.²⁻⁵ However, the rate of recurrent ISR is high, particularly in diffuse ISR.^{2,6,7} Therefore, debulking techniques that use different devices have been studied.⁸⁻¹⁰

In an animal model, rotational atherectomy (rotablation) has been shown to result in less neointima compared with PTCA.¹¹ Data from single-center studies demonstrated the feasibility and safety of rotablation in ISR and its effectiveness in debulking neointima.¹²⁻¹⁴ Furthermore, ISR patients treated with rotablation showed a lower incidence of angina and reinterventions compared with PTCA alone.^{15,16} Data from nonrandomized studies, however, indicated a wide range of clinical or angiographic restenosis.^{7,13,14}

Received August 1, 2001; revision received November 27, 2001; accepted November 27, 2001.

From the Medizinische Klinik I (J.v.D., P.K.H., R.H., H.G.K.), Universitätsklinikum, Rheinisch-Westfaelische Technische Hochschule Aachen, Germany; Johann Gutenberg Universität (U.D.), Mainz, Germany; Klinik Dr Müller (S.S.), Munich, Germany; Spedali Civil (L.N.), Brescia, Italy; Herzzentrum Bad Krozingen (H.J.B.), Germany; University Hospital Jean-Minot (F.S.), Besancon, France; King's College Hospital (M.T.), London, UK; Centre Hospitalier Privé St Martin (P.C.), Caen, France; Cardiothoracic Centre (D.R.R.), Liverpool, UK; Hospital Gregorio Marañon (E.G.), Madrid, Spain; Universitätsklinikum Eppendorf (C.W.H.), Hamburg, Germany; and Institut für Statistik und Biometrie (T.R.), Universität zu Köln, Köln, Germany.

Correspondence to Jürgen vom Dahl, MD, FESC, Medizinische Klinik II, Kliniken MariaHilf GmbH, Viersener Str 450, D-41063 Moenchengladbach, Germany. E-mail jvomdahl@post.klinikum.rwth-aachen.de

© 2002 American Heart Association, Inc.

Circulation is available at <http://www.circulationaha.org>

The aim of this randomized study was to compare rotablation followed by adjunctive low-pressure PTCA (ROTA group) with PTCA alone (PTCA group).

Methods

Study Design and Objectives

ARTIST was a prospective and randomized multicenter trial performed at 24 centers in Europe (see Appendix). Balance between treatment arms within the centers was achieved by randomizing in blocks. The design permitted crossover to the alternative treatment when the allocated treatment failed. All local investigators were required to have sufficient experience with the ROTA device (≥ 50 procedures). The local ethics committees approved the study protocol, and patients gave written, informed consent.

The primary end point was comparison of minimal luminal diameter (MLD) assessed from quantitative coronary angiography (QCA) at 6 months after treatment. Secondary end points were safety and efficacy (short-term success), event-free survival, and restenosis ($>50\%$ diameter reduction) of the target lesion after 6 months.

Study Population

Patients fulfilled the following inclusion criteria: (1) angina and/or objective evidence of target vessel-related ischemia, (2) documented ISR $>70\%$ by visual assessment within a stent ± 5 mm of the stent edges, (3) stent diameter ≥ 2.5 mm (balloon during implantation), (4) ISR as the only lesion for treatment, (5) length of ISR of 10 to 50 mm by visual assessment, and (6) lesion accessible for rotablation.

Patients were excluded for the following reasons: (1) acute myocardial infarction within the previous month, (2) left ventricular ejection fraction $<30\%$, (3) evidence of intraluminal thrombus or dissection, (4) unprotected ostial stenoses, (5) missing visualization of the distal lumen after crossing with a guidewire, (6) stents obviously not fully expanded, (7) stents at or directly distal to a bend $>45^\circ$, (8) stents implanted within the previous 3 months, and (9) stents with a classic coil design that might impair QCA.

Interventional Procedures

The rotational angioplasty device (Boston Scientific) was used as described previously.¹³ An attempted burr:artery (stent) ratio of ≥ 0.7 was required by protocol. The use of $\geq 160,000$ rpm was initially proposed; during the study, this was changed to $\geq 140,000$ rpm. Operators were urged to avoid drops ≥ 5000 rpm. Adjunctive PTCA was performed with a balloon 0.25 to 0.5 mm larger than during stent implantation with a pressure ≤ 6 atm. If the investigator was not satisfied with the angiographic result, higher pressures in 2-atm steps were allowed.

In the PTCA group, angioplasty was performed according to local routine without adjunctive procedures unless clinically indicated. The choice of balloons and details of the procedure were at the discretion of the investigator.

The decision to perform additional procedures, particularly coronary stenting, within the target lesion was at the investigator's discretion but limited to cases judged absolutely necessary. Laser energy or other atherectomy devices during the procedure were not permitted.

QCA

Angiography was performed according to common standards for off-line QCA from digitized cineangiograms with the AWOS Version 4.7 (Siemens) in the core laboratory.¹⁷⁻²⁰ Identical projections were used and analyzed at baseline, after treatment and at 6 months. Restenosis at follow-up was defined as a diameter stenosis of $>50\%$ within the stent ± 5 mm. In the case of unscheduled angiograms with subsequent revascularization of the target vessel, these angiograms were analyzed.

TABLE 1. Demographics and Baseline Characteristics

	PTCA (n=146)	ROTA (n=152)	P
Age, y	60.5 \pm 10.2	62.1 \pm 10.8	0.16
Sex, % men	81.5	78.9	0.66
CCS angina class III or IV	44.4	56.1	0.06
Diabetes	24.7	25.7	0.89
Prevalence of ≥ 3 coronary risk factors	56.2	54.6	0.82
Previous MI	46.6	47.4	0.91
Previous CABG	5.5	7.9	0.49
Ejection fraction	61.7 \pm 11.9	59.4 \pm 13.1	0.16

Values are mean \pm SD or %. CCS indicates Canadian Cardiovascular Society; MI, myocardial infarction; and CABG, coronary artery bypass graft.

Intravascular Ultrasound

The use of intravascular ultrasound (IVUS) was mandatory only in the IVUS substudy and was performed with a single-element 30-MHz transducer (Clearview Ultracross, Boston Scientific) at a pull-back speed of 0.5 mm/s.

Studies were recorded on S-VHS tape for off-line analysis at the core laboratory with cross-sectional area (CSA) measurements throughout the entire stent length.²¹⁻²³ Each border was traced three times, and the results were averaged.

Concomitant Medication

Patients received a bolus of 10 000 to 15 000 IU heparin before the intervention. Supplementary heparin was used under activated clotting time monitoring (≥ 250 s). All patients were continuously treated with aspirin and ticlopidine 500 mg/d for 2 weeks. Unless clinically necessary, the protocol discouraged the administration of glycoprotein IIb/IIIa inhibitors.

Clinical Follow-Up

In-hospital complications (major adverse cardiac events [MACEs]) were defined as tamponade, myocardial infarction (new Q waves and/or creatine kinase and creatine kinase MB $>2\times$ normal), target vessel reintervention, and death. Malfunction of the investigational device and/or stent destruction were also considered MACEs. Six-month event-free survival was calculated as survival without MACEs or target vessel revascularization before the planned follow-up angiography.

Statistical Analysis

Sample size was based on the continuous variable change in MLD assessed from QCA. It was estimated that 300 patients randomly assigned to both treatment arms were required to detect a difference of 0.4 SD of MLD change (α value, 0.05; β value, 0.2) resulting in a statistical power of 80%. Presented values are mean \pm SD. Descriptive statistical analysis was performed for all variables. The Fisher exact test and Wilcoxon rank sum test were performed. Linear regression analysis was used for a correlation between pairs of metric variables. Logistic regression models analyzed the influence on binary outcome variables (eg, restenosis). A *P* value <0.05 was considered significant.

Results

Patient Population and Baseline Lesion Characteristics

Two hundred ninety-eight patients were randomly assigned to PTCA (n=146) or ROTA (n=152). Baseline demographics and clinical characteristics are presented in Table 1. There were no significant differences regarding baseline stent and lesion characteristics (Table 2). Lesion length by visual

TABLE 2. Baseline Stent and Lesion Characteristics

	PTCA (n=146)	ROTA (n=152)	<i>P</i>
Stents			
Implantation interval, months	6.7±3.2	7.0±4.4	0.92
Length, mm	19.9±9.1	18.6±6.9	0.43
Diameter, mm	3.15±0.51	3.14±0.47	0.83
Implantation pressure, atm	12.6±3.2	12.1±2.9	0.15
Lesions			
Diameter stenosis, %	80.4±11.8	80.2±11.3	0.80
Complete occlusions, %	5.5	5.3	1.0
Length by QCA, mm	13.6±8.0	13.6±7.7	0.71
Localization, %			
LAD	41.1	50.0	0.13
LCX	14.4	16.4	0.23
RCA	38.4	31.6	0.63
Left diagonal, marginal branch	6.8	2.6	0.10

Values are mean±SD. LAD indicates left anterior descending; LCX, left circumflex; and RCA, right coronary artery.

assessment was 16.6±7.8 mm (ROTA) and 19.3±10.4 mm (PTCA).

Procedural Characteristics and Clinical Success

Procedural characteristics are presented in Table 3. The local investigators judged 89% (130/146) of the patients in the PTCA group and 88% (134/152) of those in the ROTA group to have a procedural success (final diameter stenosis of ≤30% with randomized treatment only). The main reason for failure was additional stenting (PTCA, 13 patients; ROTA, 13 patients). The rate of treatment crossovers was 0.7% (1/146) and 5.3% (8/152) for PTCA and ROTA patients, respectively ($P=0.037$). The proportions of patients who had a clinical success (procedural success with the randomized strategy in absence of MACEs), were 86% (125/146) for PTCA and 84% (127/152) for ROTA. Success with any device including stenting was 95% (139/146) in the PTCA group and 95% (144/152) in the ROTA group. Although not statistically significant, more patients in the ROTA group (14%) than in

TABLE 3. Procedural Characteristics

	PCTA (n=146)	ROTA (n=152)	<i>P</i>
Burr size, mm	...	2.08±0.26	...
Burr ≥2 mm, %	...	77	...
No. burrs per patient	...	1.8±0.8	...
Burring time, s	...	134±100	...
Burr:artery ratio (QCA)	...	0.8±0.1	...
Burr:stent ratio	...	0.7±0.1	...
Maximal balloon size, mm	3.17±0.42	3.29±0.44	0.012
Balloon size ≥3.0 mm, %	89.6	89.5	1.0
Balloon:artery ratio (QCA)	1.22±0.2	1.28±0.2	0.013
Maximal inflation pressure, atm	12.7±3.2	6.1±3.3	<0.0001
Inflation pressure >10 atm, %	68.5	7.2	<0.0001

Values are mean±SD.

TABLE 4. Complications During Hospital Stay (%)

	PTCA (n=146)	ROTA (n=152)	<i>P</i>
Any complication	7.5	13.8	0.09
Death	0.7	0	0.49
MI	1.4	4.6	0.17
CABG	0.7	1.3	1.0
PTCA	2.7	1.3	0.44
Tamponade	0	1.3	0.50
Puncture site complications	2.7	5.3	0.38

CABG indicates coronary artery bypass graft.

the PTCA group (8%) experienced MACEs or puncture site complications during hospital stay (Table 4).

After 6 months (Figure 1), 20.4% of the patients in the ROTA group had a predefined event. In contrast, 91.1% of the patients treated with PTCA were event free ($P=0.005$).

Angiographic Results

Figure 2 illustrates the patients' eligibility for follow-up angiography. Either after the planned 6-month interval or earlier for recurrent angina, 93.8% of patients in the PTCA arm and 92.5% in the ROTA arm underwent angiography.

While there was no difference in MLD before and immediately after the intervention, at 6 months, the change (net gain) in MLD was significantly greater ($P=0.0019$) for the PTCA group than for the ROTA group (Table 5). Similar results were obtained for percent diameter stenosis (Table 5). Significantly more patients in the ROTA group (65%) presented at 6 months with restenosis >50% compared with the PTCA group (51%). Also, there were significantly more patients in the ROTA (7%) than PTCA group (1%) with complete vessel occlusion. With regard to the restenosis location (stent body or edges) or length (focal versus diffuse), there were no significant differences, but a trend to more diffuse restenoses after ROTA.

By multivariate regression analysis, baseline diameter stenosis ($P=0.0012$) and lesion length ($P=0.0017$) were the most powerful predictors of restenosis. However, the use of rotablation was not an independent predictor of recurrent restenosis ($P=0.07$).

The overall need for a reintervention at the target lesion was 31% (45/146) in the PTCA group and 39% (60/152) in the ROTA group ($P=$ not significant).

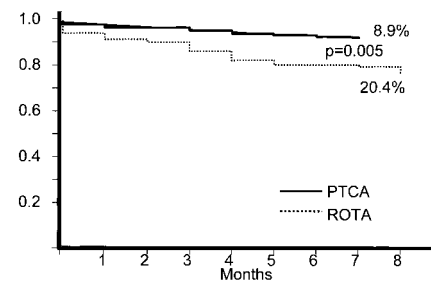


Figure 1. Event-free survival curves (absence of death, myocardial infarction, or clinically driven target lesion reintervention) during the follow-up. Reinterventions after the scheduled follow-up angiography are not included in the curves.




Figure 2. Flow chart of patients course and eligibility for clinical and angiographic follow-up (F-U) in both groups.

IVUS Results

IVUS during the intervention and at follow-up was used in a substudy involving 45 patients in the PTCA group and 41 patients in the ROTA group without significant baseline differences (Table 6). There was a significant decrease of the neointimal CSA after rotablation indicating effective debulking. Additional PTCA with low pressure did further enlarge the lumen with decrease of the in-stent neointimal CSA but did not result in additional stent over-expansion. In contrast, PTCA with higher pressures as applied in the PTCA group resulted in a significant increase of stent CSA. Neointimal tissue growth between intervention and follow-up was not significantly different between the two groups. Because of the larger stent diameter in the PTCA arm, the resulting lumen obstruction caused by neointima was less severe as compared with ROTA.

Discussion

This trial is the first multicenter study comparing two conventional treatment strategies for ISR. There were no differences between the two approaches regarding the short-term success rate. However, the primary study end point—change in MLD after 6 months—was significantly worse in patients undergoing ROTA followed by low-pressure PTCA

TABLE 5. QCA Results

	PTCA (n=146)	PTRA (n=152)	P
Reference vessel diameter, mm	2.65±0.4	2.63±0.45	0.67
Minimal luminal diameter, mm			
Pretreatment	0.53±0.31	0.54±0.31	0.81
Post-treatment	1.87±0.34	1.90±0.37	0.57
Short-term gain	1.33±0.43	1.35±0.38	0.62
Six months	1.20±0.56	0.99±0.62	0.008
Late loss	0.67±0.53	0.91±0.57	0.0015
Net gain	0.67±0.54	0.45±0.57	0.0019
Diameter stenosis, %			
Pre-treatment	80.4±11.8	80.2±11.3	0.80
Post-treatment	29.0±9.6	28.6±12.3	0.62
Six months	55.7±19.9	63.6±22.3	0.005
Change (gain)	24.8±20.3	16.7±21.9	0.002
Restenosis (>50% diameter stenosis), %	51.2	64.8	0.039

Values are mean±SD.

TABLE 6. IVUS Results

	PTCA (n=37)	ROTA (n=41)	P
Before intervention, mm ²			
Reference lumen CSA	7.3±2.6	6.3±3.2	0.43
Minimal lumen CSA	1.3±0.5	1.2±0.5	0.72
Minimal stent CSA	5.6±1.5	5.1±1.9	0.58
Neointima CSA	3.7±1.5	3.2±1.2	0.27
After rotablation, mm ²			
Minimal lumen CSA	...	2.6±0.9	...
Minimal stent CSA	...	5.0±1.8	...
Neointima CSA	...	2.2±1.3	...
After PTCA, mm ²			
Minimal lumen CSA	4.6±1.4	3.9±1.1	<0.05
Minimal stent CSA	6.7±1.7	5.3±1.7	<0.01
Neointima CSA	2.0±0.8	1.7±1.0	<0.05
Follow-up, mm ²			
Minimal lumen CSA	2.7±1.7	2.6±1.3	0.72
Minimal stent CSA	6.6±1.6	5.5±2.1	<0.005
Neointima CSA	3.4±1.4	2.4±1.0	<0.01

Values are mean±SD.

compared with patients treated with conventional PTCA alone.

Procedural Results and In-Hospital Outcome

The procedural data indicate that, in most cases with diffuse ISR, the use of the rotational atherectomy device is feasible and safe. Because the investigators, by intention and protocol, did not use IVUS during all interventions, a proportion of patients with suboptimally expanded stents, not visible by fluoroscopy, had to be expected. Therefore, the crossover rate in the ROTA group was higher compared with the PTCA group where not fully expanded stents could be passed with the balloon and subsequently adequately expanded. In the majority of ROTA cases with crossover, the investigators reported that they had difficulties crossing the entire lesion. Despite this disadvantage, previous reports^{8,12,13,16} did not find evidence for stent destruction by the device.

There were no differences between the groups with regard to the incidence of MACE recorded during hospital stay. However, because of the larger sheaths used in the ROTA arm and the prophylactic insertion of transient pacemakers in some cases, there were more puncture site complications after rotablation. Additionally, the investigators reported significantly more minor cath-laboratory observations, such as transient vessel spasm, arrhythmias, and slow flow in the ROTA group.

Despite the more aggressive approach using the atherectomy device, the need for additional stenting was similar, and serial enzyme measurements revealed no difference between the groups.

Long-Term Outcome and Comparison to Alternative Mechanical Strategies

Both treatment strategies resulted in a high restenosis rate. The recurrence rate of 51% in the PTCA arm is similar to

those observed in comparable studies with diffuse ISR.^{6,7,24} In contrast to previous reports, athero-ablation of diffuse ISR did not result in improved long-term outcome. Patients undergoing rotablation had a lower event-free survival rate and worse angiographic results at follow-up. Probably the major explanation for this unexpected outcome was the relatively small MLD and stent diameter achieved at the end of the procedure.

Previous studies of rotablation for ISR indicated a wide variation of outcome ranging from 26% (reintervention)¹⁴ to 49% (angiographic restenosis).¹³ Most studies with ISR patients demonstrated a difference between angiographical restenosis and clinically driven reinterventions of 15 to 20%. Furthermore, a study using excimer laser angioplasty with systematic angiographic follow-up indicated a similar restenosis rate of 54%.²⁵

Preliminary data contrary to ARTIST have been reported recently from the single-center Randomized Trial of PTCA versus Rotablator for Diffuse In-Stent Restenosis (ROSTER).²⁶ Patients undergoing ROTA had a more favorable outcome compared with patients treated with PTCA. As a main difference to ARTIST, all patients had baseline IVUS, which resulted in an exclusion of 1/3 of screened patients. Furthermore, 31% of the patients in the PTCA arm group had additional stenting compared with only 10% in the ROTA arm group.

Why Did Rotational Atherectomy Fail to Improve Outcome?

The mechanisms of PTCA and debulking strategies for ISR have been described in detail elsewhere.^{14,21,27,28} Our hypothesis was that debulking of the neointima would indeed lead to less remaining tissue inside the stent compared with PTCA alone and would subsequently result in less persistent tissue after adjunctive PTCA. This was thought to minimize the vessel trauma, which should consecutively reduce the recurrent neointimal proliferation. The IVUS results support these assumptions in part. ROTA led to significant ablation of in-stent neointima leaving less tissue inside the stent with nearly no tissue extrusion through the struts. However, stent diameters remained, as expected, unchanged and were only slightly increased after PTCA. In contrast, after angioplasty in the PTCA group, there was significant tissue extrusion and stent expansion, which lead to larger stent diameters at follow-up and less restenosis despite the fact that the amount of neointimal tissue within the stents was similar in both groups. It can be speculated that high-pressure inflations in the ROTA group would lead to larger stent diameters acutely with a lower restenosis rate.

Limitations

The study protocol did not include IVUS in all patients. This should simulate common practice in most interventional laboratories in Europe. Thus, suboptimally deployed stents could not be ruled out, which might have been a disadvantage particularly for the ROTA group where stent under-expansion could not be corrected by high-pressure inflations.

A more aggressive atherectomy strategy with larger burrs might have led to different results. However, by QCA the

burr:artery ratio was high enough to result in sufficient tissue removal within the stent.

The induction of shear stress and heat during rotablation within the stents may affect the restenosis cascade after the procedure. Platelet activation and subsequent aggregation resulting in thrombus formation has been described and can be successfully reduced by the administration of abciximab.²⁹ Thus, particularly in patients undergoing rotablation for ISR, the additional use of glycoprotein IIb/IIIa inhibitors might be advantageous, which was discouraged in this study to avoid imbalances between the groups.

Clinical Implications and Conclusions

Despite the fact that rotational atherectomy leads to true tissue removal within restenosed stents, it does, in combination with low-pressure balloon angioplasty, not reduce the rate of recurrent ISR as compared with balloon angioplasty alone. This randomized multicenter study could not prove that rotational atherectomy has a favorable long-term outcome. This may be in part a result of the chosen approach using only low-pressure inflations after rotablation and is probably due to the fact that balloon angioplasty with higher pressures leads to more stent over-expansion, which results in larger stent dimensions acutely and at 6-month follow-up.

Appendix

Steering Committee

J. vom Dahl, HG. Klues (Aachen, Germany), J. Marco (Toulouse, France), E. Garcia (Madrid, Spain), D. Auth (Redmond, Washington), M. Thomas (London, United Kingdom), M. Scharl (Berlin, Germany).

Data and Safety Monitoring Board

P. Kramer (Omaha City, Nebraska), P. Hugenholtz (Rotterdam, The Netherlands), H. Wellens (Maastricht, The Netherlands), B. Meier (Bern, Switzerland), R. Erbel (Essen, Germany).

Core Laboratories

Study Coordinating Center: RWTH Aachen, Germany (P.K. Haager); Angiographic Core Laboratory: University Mainz, Germany (U. Dietz); IVUS Core Laboratory: RWTH Aachen, Germany (R. Hoffmann, P.K. Haager); Statistics: University Köln, Germany (T. Reineke).

Participating Centers

W. Wijns, G. Heyndrickxs (Aalst, Belgium); J. Marco, J. Fajadet (Toulouse, France), J.P. Bassand, F. Schiele (Besançon, France), P. Meyer (St. Laurent du Var, France); H. Le Breton (Rennes, France); P. Commeau (Caen, France); J. vom Dahl, H.G. Klues (Aachen, Germany); H.J. Rupprecht, U. Dietz (Mainz, Germany); C.W. Hamm (Hamburg, Germany); B. Hennen (Homburg, Germany); H. Mudra (Munich, Germany); S. Silber (Munich, Germany); H.J. Buettner (Bad Krozingen, Germany), M. Scharl (Berlin, Germany); G. Gaul (Wien, Austria); L. Niccoli (Brescia, Italy); A. Colombo, C. de Mario (Milan, Italy); M. Quarles van Ufford (Breda, The Netherlands); E. Garcia (Madrid, Spain); R. Seabra-Gomes (Lisbon, Portugal); M. de Belder (Middlesborough, United Kingdom); M. Thomas (London, United Kingdom); D.R. Ramsdale (Liverpool, United Kingdom).

Acknowledgment

This study was supported by Boston Scientific Europe Corporation, Paris.

References

1. Narins CR, Holmes DR, Topol EJ. A call for provisional stenting: the balloon is back! *Circulation*. 1998;97:1298–1305.
2. Baim DS, Levine MJ, Leon MB, et al. Management of restenosis within the Palmaz-Schatz coronary artery stent (the US multicenter experience). *Am J Cardiol*. 1993;71:364–366.
3. Reimers B, Moussa I, Akiyama T, et al. Long-term follow-up after successful repeat percutaneous intervention for stent restenosis. *J Am Coll Cardiol*. 1997;30:186–192.
4. Bauters C, Banos J-L, van Belle E, et al. Six-month angiographic outcome after successful repeat percutaneous intervention for in-stent restenosis. *Circulation*. 1998;97:318–321.
5. Bossi I, Klersy C, Black AJ, et al. In-stent restenosis: long-term outcome and predictors of subsequent target lesion revascularization after repeat balloon angioplasty. *J Am Coll Cardiol*. 2000;35:1569–1576.
6. Mehran R, Dangas G, Abizaid AS, et al. Angiographic patterns of in-stent restenosis: classification and implications for long-term outcome. *Circulation*. 1999;100:1872–1878.
7. Kini A, Marmur JD, Dangas G, et al. Angiographic patterns of in-stent restenosis and implications on subsequent revascularization. *Catheter Cardiovasc Interv*. 2000;49:23–29.
8. Bottner RK, Hardigan KR. High-speed rotational atherectomy for in-stent restenosis. *Cathet Cardiovasc Diagn*. 1997;40:144–149.
9. Mahdi NA, Pathan AZ, Harrell L, et al. Directional coronary atherectomy for the treatment of Palmaz-Schatz in-stent restenosis. *Am J Cardiol*. 1998;82:1345–1351.
10. Koester R, Hamm CW, Seabra-Gomes R, et al. Laser angioplasty of restenosed coronary stents: results of a multicenter surveillance trial (LARS). *J Am Coll Cardiol*. 1999;34:25–32.
11. McKenna CJ, Wilson SH, Camrud AR, et al. Neointimal response following rotational atherectomy compared to balloon angioplasty in a porcine model of coronary in-stent restenosis. *Cathet Cardiovasc Diagn*. 1998;45:332–336.
12. Sharma SK, Duvvuri S, Dangas G, et al. Rotational atherectomy for in-stent restenosis: acute and long-term results of first 100 cases. *J Am Coll Cardiol*. 1998;32:1358–1365.
13. vom Dahl J, Radke P, Haager P, et al. Clinical and angiographic predictors of recurrent restenosis after percutaneous transluminal rotational atherectomy for treatment of diffuse in-stent restenosis. *Am J Cardiol*. 1999;83:862–867.
14. Mehran R, Dangas G, Mintz G, et al. Treatment of in-stent restenosis with excimer laser coronary angioplasty versus rotational atherectomy: comparative mechanisms and results. *Circulation*. 2000;101:2484–2489.
15. Lee S-G, Lee CW, Cheong S-S, et al. Immediate and long-term outcomes of rotational atherectomy versus balloon angioplasty alone for treatment of diffuse in-stent restenosis. *Am J Cardiol*. 1998;82:140–143.
16. Dauerman HL, Baim DS, Cutlip DE, et al. Mechanical debulking versus balloon angioplasty for the treatment of diffuse in-stent restenosis. *Am J Cardiol*. 1998;82:277–284.
17. Dietz U, Rupprecht HJ, Brennecke R, et al. Comparison of QCA Systems. *Int J Card Imaging*. 1997;13:271–280.
18. Dietz U, Rupprecht HJ, Woltmann J, et al. Effect of qualitative stenosis characteristics on the quality of measurements of various QCA systems. *Z Kardiol*. 1997;86:183–188.
19. Herrington DM, Siebes M, Sokol DK, et al. Variability in measures of coronary lumen dimensions using quantitative coronary angiography. *J Am Coll Cardiol*. 1993;22:1068–1074.
20. Reiber JH, van Eldik Helleman P, Visser Akkerman N, et al. Variabilities in measurement of coronary arterial dimensions resulting from variations in cineframe selection. *Cathet Cardiovasc Diagn*. 1988;14:221–228.
21. Radke P, Klues H, Haager P, et al. Mechanisms of acute luminal gain and recurrent restenosis after rotational atherectomy of diffuse in-stent restenosis. *J Am Coll Cardiol*. 1999;34:33–39.
22. Mintz GS, Griffin J, Chuang YC, et al. The reproducibility of the intravascular ultrasound assessment of stent implantation in saphenous vein grafts. *Am J Cardiol*. 1995;75:1267–1270.
23. Nissen S, Gurley J, Grines CI, et al. Intravascular ultrasound assessment of lumen size and wall morphology in normal subjects and patients with coronary artery disease. *Circulation*. 1991;84:1087–1099.
24. Waksman R, White R, Chan R, et al. Intracoronary gamma-radiation therapy after angioplasty inhibits recurrence in patients with in-stent restenosis. *Circulation*. 2000;101:2165–2171.
25. Koester R, Kaehler J, Terres W, et al. Six-month clinical and angiographic outcome after successful excimer laser angioplasty for in-stent restenosis. *J Am Coll Cardiol*. 2000;36:69–74.
26. Sharma SK, Annapoorna SK, King T, et al. Multivariate predictors of target lesion revascularization in the Randomized Trial of PTCA versus Rotablator for Diffuse In-Stent Restenosis (ROSTER). *J Am Coll Cardiol*. 2001;37:55A. Abstract.
27. Mehran R, Mintz GS, Popma JJ, et al. Mechanisms and results of balloon angioplasty for the treatment of in-stent restenosis. *Am J Cardiol*. 1996;78:618–622.
28. Schiele F, Meneveau N, Seronde MF, et al. Predictors of event-free survival after repeat intracoronary procedure for in-stent restenosis: study with angiographic and intravascular ultrasound imaging. *Eur Heart J*. 2000;21:754–762.
29. Williams MS, Collier BS, Väänänen HJ, et al. Activation of platelets in platelet-rich plasma by rotablation is speed dependent and can be inhibited by abciximab (c7E3 Fab; ReoPro). *Circulation*. 1998;98:742–748.