

S. Silber, U. Klein, L. Goppel, H. Rinke, H. Petri, M. Weber, W. Rudolph

Klinik für Herz- und Kreislauferkrankungen (Direktor: Prof. Dr. W. Rudolph), Deutsches Herzzentrum München

Thallium-201 Myocardial Imaging in Patients with Hypertrophic Cardiomyopathy and with Right Ventricular Overload

Summary

Thallium-201 scintigrams were recorded, at rest, in 23 patients with hypertrophic cardiomyopathy, 51 patients with right ventricular pressure or volume overload and in 18 healthy subjects. The thickness of the septum (S) and the left ventricular (LV) and right ventricular free walls in the scintigram were assessed. In the 23 patients with hypertrophic cardiomyopathy the scintigraphically measured thicknesses of the septum and the left ventricular free wall were significantly greater than the echocardiographically measured enddiastolic wall thicknesses, but corresponded well with the sum of the echocardiographically measured enddiastolic wall thickness and the amplitude of motion. The S/LV ratio was ≥ 1.3 in all patients with hypertrophic cardiomyopathy in the echocardiogram, but only in 35% in the scintigram. This can be accounted for by the fact that the scintigraphic method also encompasses wall motion and, thus, renders inaccuracies since in patients with hypertrophic cardiomyopathy the septal motion is hypokinetic and the left ventricular free wall motion is unimpaired. The right ventricular free wall was visualized slightly in only 16.5% of the controls. In contrast, the right ventricular free wall was readily visualized, and demonstrated a thickness of more than half of that of the left ventricular free wall, in each of the 51 patients with right ventricular overload. No correlation was found between the scintigraphically measured thickness of the right ventricular free wall and either the extent of pressure or volume overload or the extent of right ventricular strain pattern in the ECG.

The thallium-201 scintigram has not proved to be a sensitive indicator of the presence of hypertrophic cardiomyopathy. The method is, however, particularly sensitive in the detection of right ventricular pressure or volume overload.

Zusammenfassung: Thallium-201-Szintigraphie bei Patienten mit hypertropher Kardiomyopathie und mit Rechtsherzbelastung

Bei 23 Patienten mit hypertropher Kardiomyopathie, bei 51 Patienten mit einer rechtsventrikulären Druck- bzw. Volumenbelastung und bei 18 Patienten ohne organische Herzerkrankung wurden Thallium-201-Szintigramme unter Ruhebedingungen angefertigt. Szintigraphisch wurde die Dicke des Septums (S) und der linksventrikulären (LV) bzw. der rechtsventrikulären freien Wand bestimmt. Bei den 23 Patienten mit hypertropher Kardiomyopathie waren die szintigraphisch gemessenen Dicken des Septums und der linksventrikulären freien Wand statistisch signifikant höher als die enddiastolischen echokardiographischen Wanddicken, zeigten jedoch eine gute Übereinstimmung mit der Summe aus enddiastolischer Wanddicke und Bewegungsamplitude. Der Quotient S/LV war echokardiographisch bei allen Patienten mit hypertropher Kardiomyopathie $\geq 1,3$, szintigraphisch jedoch nur bei 35% der Patienten. Dies beruht darauf, daß das Septum bei den Patienten mit hypertropher Kardiomyopathie eine Hypokinesie, die linksventrikuläre freie Wand jedoch eine nicht eingeschränkte Beweglichkeit zeigt und somit der Fehler, der durch die szintigraphisch miterfaßte Wandbewegung entsteht, bei der linksventrikulären freien Wand größer ist als beim Septum. Die rechtsventrikuläre freie Wand stellte sich nur in 16,5% der Normalpersonen angedeutet dar. Bei allen 51 Patienten mit einer rechtsventrikulären Druck- oder Volumenbelastung war die rechtsventrikuläre freie Wand deutlich sichtbar und dicker als die Hälfte der linksventrikulären freien Wand. Eine Korrelation der szintigraphisch gemessenen rechtsventrikulären Wanddicken zum Ausmaß der Druck- oder Volumenbelastung und dem Ausmaß der Rechtsherzbelastungszeichen im Ekg bestand nicht.

Somit stellt die Thallium-201-Szintigraphie keine sensitive Methode zur Diagnostik der hypertrophen Kardiomyopathie dar, sie besitzt aber zur Erkennung einer rechtsventrikulären Druck- oder Volumenbelastung eine außerordentlich hohe Sensitivität.

Hypertrophic cardiomyopathy as well as right ventricular pressure overload can be diagnosed in the thallium-201 scintigram [2, 12, 13]. Studies concerned with the sensitivity of this method in the presence of hypertrophic cardiomyopathy and those concerned with correlations between scintigraphically measured wall thickness and right ventricular pressure are not available, as well as studies in patients with right ventricular volume overload.

The purpose of this study was to determine the frequency with which hypertrophic cardiomyopathy and whether a right ventricular volume overload can be detected in the thallium-201 scintigram and to assess, if

correlations exist between the scintigraphically measured thickness of the right ventricular free wall and the extent of the pressure and volume overload as well as with that of a right ventricular-strain pattern in the ECG.

Material and Methods

A total of 92 patients were studied. In 23 patients, the diagnosis of hypertrophic cardiomyopathy was documented in the left ventricular angiogram, by simultaneous pressure recordings in the aorta and left ventricle and in the echocardiogram. Cardiac catheterization in 51 of the patients documented the presence of right

ventricular pressure or volume overload. 16 patients had right ventricular volume overload (14 with atrial septal defect, two with isolated tricuspid insufficiency), 30 patients had right ventricular pressure overload (twelve with mitral stenosis and pulmonary hypertension, five with pulmonic stenosis, four with cor pulmonale, five with Eisenmenger syndrome, three with tetralogy of Fallot, one with constrictive pericarditis and marked pressure elevation in the pulmonary circulation). Five patients had biventricular overload (four with mitral insufficiency and one with hypertensive heart disease, all of whom had pulmonary hypertension). 18 patients in whom organic heart disease could be ruled out served as controls. Scintigrams were obtained at rest with an Anger-camera (Radicamera, Nuclear-Data) in six projections (AP, 30°, 45° and 60° LAO, left lateral and 30° RAO) with a low-energy-high-resolution collimator at 69–80 keV and a 20% window. 300.000 counts per image were collected ten minutes after the injection of 1,5 to 2,0 mCi thallium-201 (Duphar Co., Petten, the Netherlands). The data were stored in a small dedicated computer system (Medstor, Nuclear Data). A 10 × 1 cm lead marker was used for calibration. The thickness of the right ventricular free wall, of the septum and of the left ventricular free wall was calculated from the unprocessed images obtained in the 45° LAO projection.

In patients with hypertrophic cardiomyopathy the end-diastolic wall thickness of the septum and of the left ventricular free wall as well as their amplitude of motion were assessed echocardiographically. A ratio S/LV ≥ 1.3 was considered diagnostic for hypertrophic cardiomyopathy [5, 9].

Results

Controls

The right ventricular free wall was visualized, slightly, in only three of the 18 controls. In these patients, the scintigraphically measured wall thickness was consistently less than 1 cm. The mean scintigraphically measured thickness of the septum was 1.85 ± 0.21 cm (range 1.5 to 2.2 cm) and the thickness of the left ventricular free wall averaged 2.03 ± 0.29 cm (range 1.5 to 2.7 cm).

Hypertrophic Cardiomyopathy

The scintigraphically measured septum thickness in patients with hypertrophic cardiomyopathy (figure 1) averaged 3.32 ± 0.61 cm (range 2.2 to 3.9 cm), the mean thickness of the left ventricular free wall measured 2.79

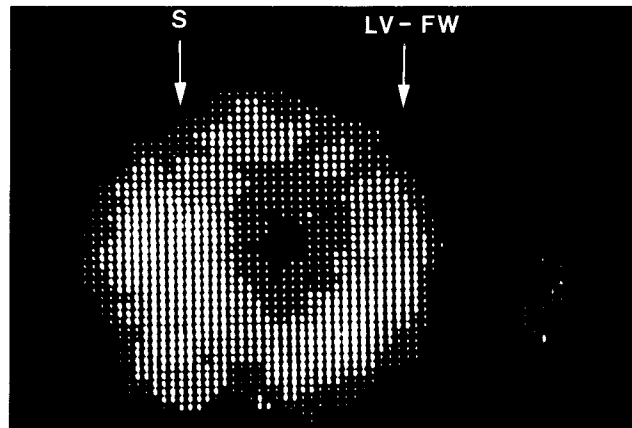


Figure 1. Thallium-201 scintigram (45° LAO projection) of a 33 year-old patient with hypertrophic cardiomyopathy. The diagnosis is confirmed by the finding of an S/LV ratio greater than 1.3. (S = septum, LV-FW = left ventricular free wall.)

± 0.52 cm (range 1.8 to 4.2 cm). As compared with controls, this group demonstrated significantly ($p < 0.05$) increased thickness of the septum and the left ventricular free wall (figure 2). Compared with the S/LV ratio of 0.92 ± 0.10 (range 0.77 to 1.0) found in controls, a significant increased mean value of 1.25 ± 0.30 (range 0.88 to 1.96) was obtained from patients with hypertrophic cardiomyopathy. In 35% of these patients the S/LV ratio was ≥ 1.3 . The echocardiographically measured enddiastolic septum thicknesses in patients with hypertrophic cardiomyopathy were 2.64 ± 0.51 cm (range 1.2 to 3.2 cm), the enddiastolic thickness of the left ventricular free wall averaged 1.22 ± 0.2 cm (range 0.2 to 1.7 cm). The S/LV ratio ob-

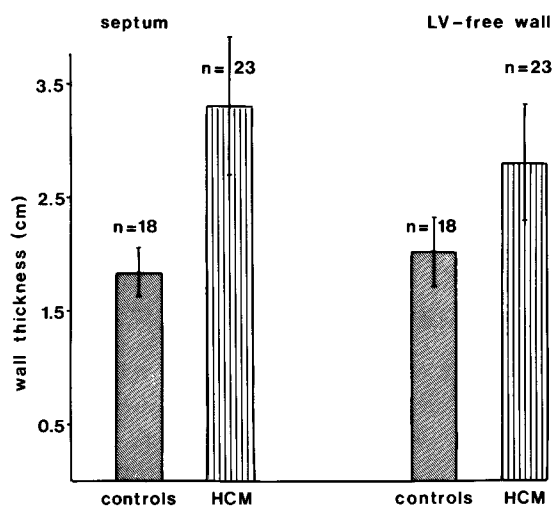


Figure 2. Scintigraphically determined wall thickness in 18 controls and 23 patients with hypertrophic cardiomyopathy (HCM). The thickness of the septum as well as the left ventricular free wall is significantly ($p < 0.05$) greater.

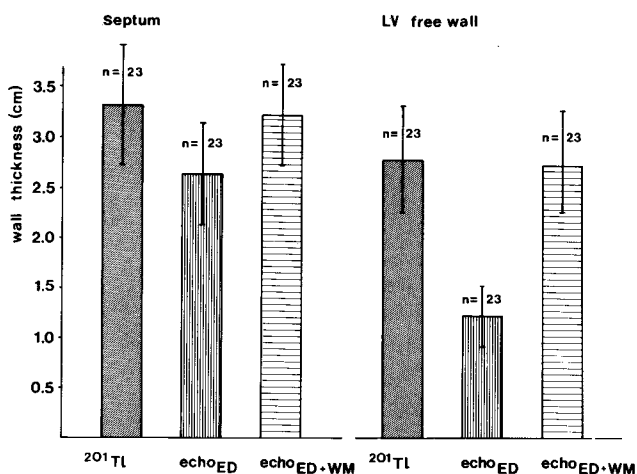


Figure 3. Comparison of the measurements of the thickness of the septum and left ventricular free wall as obtained from the thallium-201 scintigram and echocardiogram. The scintigraphically determined values for wall thicknesses in patients with hypertrophic cardiomyopathy are greater than the corresponding values obtained from the echocardiographically measured enddiastolic wall thickness, but relate well with the sum of the echocardiographically measured enddiastolic (ED) wall thickness and the amplitude of wall-motion (WM).

tained echocardiographically was ≥ 1.3 (mean 1.99 ± 0.15) in all patients. The scintigraphically measured wall thicknesses were significantly greater than the enddiastolic echocardiographic measurements (figure 3). Corresponding values can, however, be obtained if the scintigraphically measured wall thicknesses are compared with the sum of the echocardiographic enddiastolic wall thickness and the amplitude of motion. The average scintigraphically measured septum thickness of 3.32 ± 0.50 cm is in good agreement with the average sum of the echocardiographically measured enddiastolic wall thickness and the amplitude of motion of 3.3 ± 0.50 cm (figure 3). The mean scintigraphically measured wall thickness of the left ventricular free wall of 2.79 ± 0.52 cm corresponded well with the sum of the echocardiographically measured enddiastolic wall thickness and the amplitude of motion which averaged 2.70 ± 0.45 cm.

Right Ventricular Overload

In each of the 51 patients with right ventricular overload, the right ventricular free wall could be readily visualized (figures 4 and 5). In the 16 patients with right ventricular volume overload and normal right ventricular pressure, the thickness measured 2.35 ± 0.46 cm (range 1.8 to 3.1 cm, figure 6). The thickness of the left ventricular free wall averaged 2.66 ± 0.46 cm (range 2.1 to 3.4 cm) and that of the septum was 2.33 ± 0.34

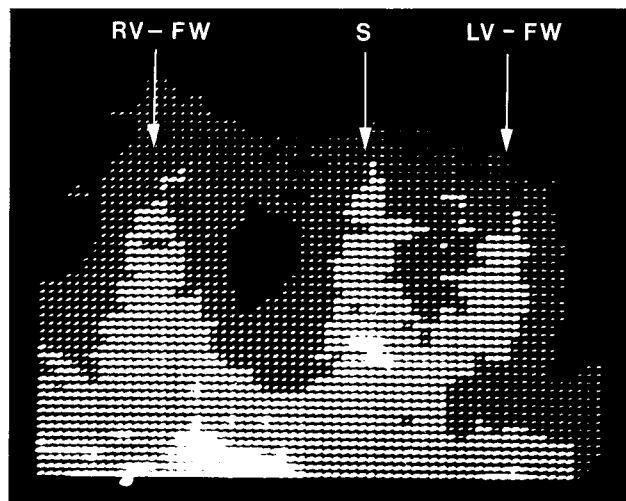


Figure 4. Thallium-201 scintigram (45° LAO projection) of a 36 year-old patient with atrial septal defect and 55% left-right shunt and normal pulmonary arterial pressure. (RV-FW = right ventricular free wall, S = septum, LV-FW = left ventricular free wall.)

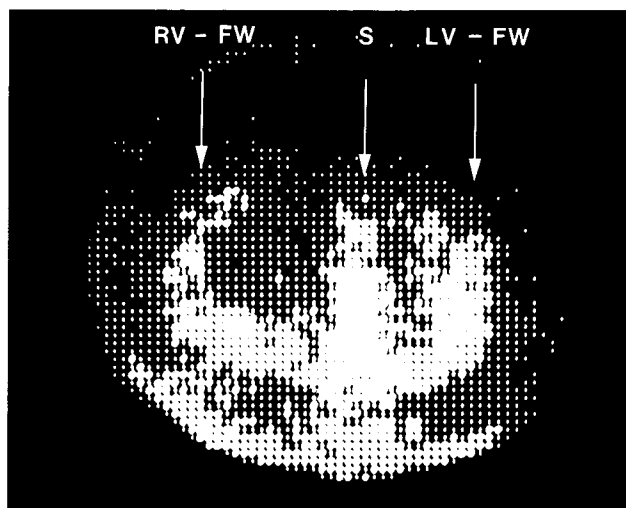
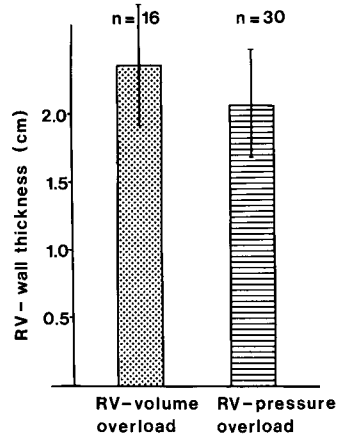


Figure 5. Thallium-201 scintigram (45° LAO projection) of a 28 year-old patient with Eisenmenger syndrome and mean pulmonary arterial pressure of 100 mm Hg, right-left shunt 20%. (RV-FW = right ventricular free wall, S = septum, LV-FW = left ventricular free wall.)

cm (range 1.9 to 2.5 cm). The ratio RV/LV was 0.89 ± 0.20 .

30 patients with right ventricular pressure overload had a mean right ventricular wall thickness of 2.09 ± 0.40 cm (range 1.3 to 3.6 cm, figure 6), a left ventricular wall thickness of 2.41 ± 0.50 cm (range 1.4 to 3.2 cm) and a mean septum thickness of 2.38 ± 0.47 cm (range 1.4 to 3.2 cm). The RV/LV ratio was 0.95 ± 0.32 . The right ventricular free wall of patients with volume overload was significantly ($p < 0.05$) thicker than that of patients with right ventricular pressure overload (figure 6).

Figure 6. Scintigraphically measured wall thickness in 16 patients with right ventricular volume overload and 30 patients with right ventricular pressure overload. Since the scintigraphic method encompasses the amplitude of wall motion as well as the wall thickness, measurements of the right ventricular free wall in patients with right ventricular volume overload were significantly ($p < 0.05$) greater than those with right ventricular pressure overload.



Five patients with right ventricular pressure overload resulting from left ventricular dysfunction (biventricular overload) displayed values for right ventricular wall thickness similar to those of patients with isolated right ventricular pressure overload, namely, 1.90 ± 0.70 cm. No correlation was found between the right ventricular pressure, flow in the pulmonary circulation and the

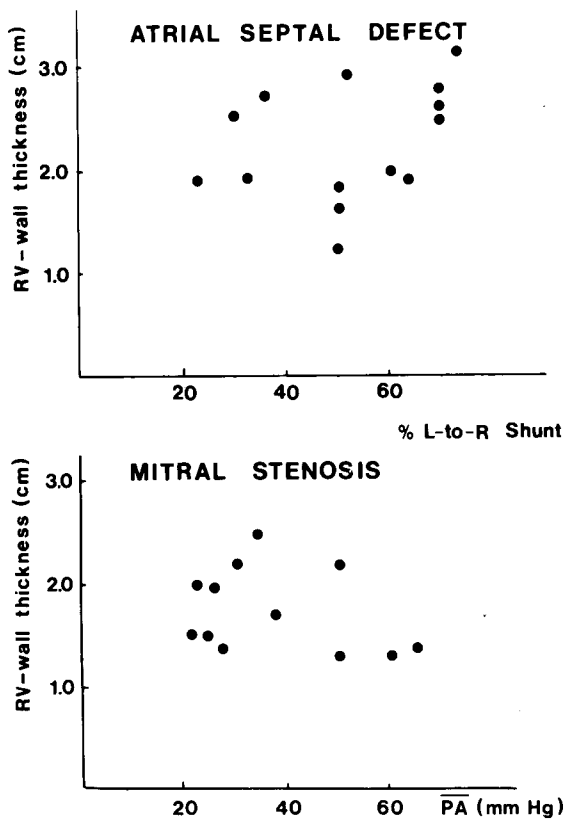


Figure 7. No correlation was found between the measured thickness of the right ventricular free wall and either the extent of the left-right shunting in patients with atrial septal defect or mean pulmonary arterial pressure in patients with mitral stenosis and pulmonary hypertension.

scintigraphically measured wall thickness in any of the groups (figure 7). Similarly, no correlation could be established between the measured wall thickness and the extent of the strain pattern in the ECG. This lack of relationship is to be expected, since 17 of the 51 patients (two of the 16 with right ventricular volume overload, ten of the 30 with right ventricular pressure overload and all five of those with biventricular overload) indeed had no signs of right ventricular strain in the electrocardiogram.

Discussion

All 23 patients studied with hypertrophic cardiomyopathy demonstrated significantly increased values for septum and left ventricular free wall thicknesses and for S/LV ratio. The S/LV ratio, however, was ≥ 1.3 only in 35% such that a diagnosis of hypertrophic cardiomyopathy based on the thallium-201 scintigram could be established only in eight of the 23 patients. In contrast, Bulkley et al. [2] reported finding a S/LV ratio ≥ 1.3 in the thallium-201 scintigram in all ten of the patients investigated. In this study, the S/LV ratio obtained echocardiographically was ≥ 1.3 in all patients. Comparison of the scintigraphically and echocardiographically measured wall thicknesses indicates that the scintigraphic values do not represent the absolute wall thickness but rather the sum of the enddiastolic wall thickness and the amplitude of motion. In hypertrophic cardiomyopathy, the echocardiographically and scintigraphically measured mean thickness of the septum differed less than of the left ventricular free wall. This finding can be explained on the basis of hypokinetic septum motion (amplitude < 5 mm), while the motion of the left ventricular free wall was unimpaired. Thus, the error inherent to the scintigraphic method is due to wall motion and is, therefore, more marked with regard to left ventricular free wall than to the septum and accounts for the finding that in 65% of the patients studied, the S/LV ratio was lower than obtained from the echocardiogram.

The right ventricular free wall could be visualized slightly in the thallium-201 scintigram in 16.5% of the controls. This is in good agreement with the incidence found by Strauss et al. [14]. The fact that the right ventricular free wall can either not be detected or only slightly visualized in healthy subjects represents lesser activity concentration [15] proportional to the moderately decreased myocardial blood flow [3, 6, 10] and to the relatively small muscle mass, as compared with the left ventricle.

An increase in blood flow induced by a rapid resting heart rate or stress testing [1] renders scintigraphic visualization of the right ventricular free wall in healthy subjects.

In addition to an increased muscle mass with subsequent elevation of the registered impulse rate, an increased myocardial blood flow may be the reason why the right ventricular free wall was visualized in each patient with atrial septal defect in spite of normal right ventricular pressures and normal right ventricular muscular thickness [4]. The finding that the right ventricular free wall thickness appears greater in patients with right ventricular volume overload than in those with right ventricular pressure overload can, thus, most probably be accounted for by the fact that the scintigraphic measurements encompass the amplitude of motion as well as the enddiastolic thickness. The scintigraphic visualization of the right ventricular free wall in right ventricular hypertrophy [8, 12, 13] can also be explained on the basis of an increased muscle mass, and possibly of an increase in myocardial blood flow [11]. The high sensitivity of the thallium-201 scintigram is documented by the fact that the right ventricular free wall was visualized in all patients with hemodynamically proven right ventricular pressure or volume overload. In contrast, electrocardiographic criteria are much less sensitive: A right ventricular strain pattern could be detected only in 66.5% of the patient population and in none of those with biventricular overload [7].

No correlation was found between the scintigraphically measured right ventricular wall thickness and the extent of the pressure or volume overload. This negative finding is, as expected, due to the previously noted encompassment of wall motion in the thickness measurements. Furthermore, the extent of hypertrophy does not necessarily correlate with the momentary findings obtained during hemodynamic measurements. Whether a more exact scintigraphic determination of wall thickness may be yielded by gating is questionable since this method prerequisites a ten-fold increase in registration time.

Thus, the thallium-201 scintigram is not a sensitive method for determining exact wall thicknesses and provides little aid in establishing the diagnosis of hyper-

trophic cardiomyopathy. This method is, however, a useful aid in the recognition of right ventricular pressure- or volume overload.

References

1. Bermann, D. S., A. F. Salel, G. D. De-Nardo, D. T. Mason: Non-invasive detection of regional myocardial ischemia using rubidium-81 and the scintillation camera. *Circulation* 52 (1975), 619.
2. Bulkley, B. H., J. Rouleau, H. W. Strauss, B. Pitt: Idiopathic hypertrophic subaortic stenosis: Detection by thallium-201 myocardial perfusion imaging. *New Engl. J. Med.* 293 (1975), 1113.
3. Cannon, P. J., R. B. Dell, E. M. Dell, Jr.: Measurement of regional myocardial perfusion in man with 133-xenon and a scintillation camera. *J. clin. Invest.* 51 (1972), 964.
4. Edwards, J., L. Cavey, H. Neufeld, R. Lester: Congenital heart disease. - Correlation of pathologic anatomy and angiocardiology. Saunders Co., Philadelphia-London 1965.
5. Henry, W. L., C. E. Clark, S. E. Epstein: Asymmetric septal hypertrophy: Echocardiographic identification of the pathognomonic anatomic abnormality of IHSS. *Circulation* 47 (1973), 225.
6. Meister, W., J. Kriener, W. Rudolph: Myokarddurchblutung im Versorgungsbereich der linken und der rechten Koronararterie bei Patienten ohne und mit koronarer Herzerkrankung. *Verh. dtsh. Ges. Kreisl.-Forsch.* 37 (1971), 156.
7. Millard, R. J. C.: The electrocardiogram in chronic lung disease. *Brit. Heart J.* 29 (1967), 43.
8. Pabst, H. W., G. Hör, H. Lichte, H. Sebening, H. Kriegel: Experience with 201-thallium in detection of myocardial infarction. *Europ. J. nucl. Med.* 1 (1976), 19.
9. Rinke, H., M. Späth, W. Rudolph: Die Mitralklappenbeweglichkeit im UKG bei der hypertrophen Kardiomyopathie mit Obstruktion (IHSS) und ihre Veränderung nach Betarezeptorenbehandlung. *Z. Kardiol. Suppl. II* (1975), 15.
10. Rudolph, W., M. Hegemann: Utility and limitations of myocardial perfusion measurement with radionuclides using a probe detector. *J. nucl. Biol. Med.* 16 (1972), 254.
11. Rudolph, W., M. Wickmayer: Die Koronardurchblutung bei Patienten mit Aortenstenose. *Z. Kreisl.-Forsch.* 58 (1969), 135.
12. Sauer, E., H. Lichte, H. Sebening, L. Lutitsky, G. Hör, S. Daum: Myokardszintigraphie mit 201-Tl bei pulmonaler Hypertonie. *Cor pulmonale chronicum: Europ. Soc. clin. respir. Physiol. and Europ. Soc. Cardiol., München* 3.-6. 3. 1976.
13. Stevens, R. M., M. G., Baird, C. F. Fuhrmann, J. Rouleau, W. R. Summer, H. W. Strauss, B. Pitt: Detection of right ventricular hypertrophy by thallium-201 myocardial perfusion imaging. *Circulation* 51/52, Suppl. II (1975), 242.
14. Strauss, H. W., D. J. Cook, B. Pitt: Importance of technical factors in recording myocardial perfusion scan with thallium-201. *7th Europ. Congr. Cardiol., Amsterdam* 20.-25. 6. 1976.
15. Strauss, H. W., K. Harrison, J. K. Langan, E. Lebowitz, B. Pitt: Thallium-201 for myocardial imaging. *Circulation* 51 (1975), 641.

Address all correspondence to: Prof. Dr. Werner Rudolph, Deutsches Herzzentrum, Klinik für Herz- und Kreislauferkrankungen, Lothstraße 11, D-8000 München 2.