

# TAXUS I

## Six- and Twelve-Month Results From a Randomized, Double-Blind Trial on a Slow-Release Paclitaxel-Eluting Stent for De Novo Coronary Lesions

Eberhard Grube, MD; Sigmund Silber, MD; Karl Eugen Hauptmann, MD; Ralf Mueller, MD; Lutz Buellesfeld, MD; Ulrich Gerckens, MD; Mary E. Russell, MD



**Background**—The TAXUS NIRx stent (Boston Scientific Corp) provides local delivery of paclitaxel via a slow-release polymer coating. The TAXUS I trial was the first in-human experience evaluating safety and feasibility of the TAXUS NIRx stent system compared with bare NIR stents (control) (Boston Scientific Corp) for treatment of coronary lesions.

**Methods and Results**—The TAXUS I trial was a prospective, double-blind, three-center study randomizing 61 patients with de novo or restenotic lesions ( $\leq 12$  mm) to receive a TAXUS ( $n=31$ ) versus control ( $n=30$ ) stent (diameter 3.0 or 3.5 mm). Demographics, lesion characteristics, clinical outcomes were comparable between the groups. The 30-day major adverse cardiac event (MACE) rate was 0% in both groups ( $P=NS$ ). No stent thromboses were reported at 1, 6, 9, or 12 months. At 12 months, the MACE rate was 3% (1 event) in the TAXUS group and 10% (4 events in 3 patients) in the control group ( $P=NS$ ). Six-month angiographic restenosis rates were 0% for TAXUS versus 10% for control ( $P=NS$ ) patients. There were significant improvements in minimal lumen diameter ( $2.60 \pm 0.49$  versus  $2.19 \pm 0.65$  mm), diameter stenosis ( $13.56 \pm 11.77$  versus  $27.23 \pm 16.69$ ), and late lumen loss ( $0.36 \pm 0.48$  versus  $0.71 \pm 0.48$  mm) in the TAXUS group (all  $P < 0.01$ ). No evidence of edge restenosis was seen in either group. Intravascular ultrasound analysis showed significant improvements in normalized neointimal hyperplasia in the TAXUS ( $14.8 \text{ mm}^3$ ) group compared with the control group ( $21.6 \text{ mm}^3$ ) ( $P < 0.05$ ).

**Conclusions**—In this feasibility trial, the TAXUS slow-release stent was well tolerated and showed promise for treatment of coronary lesions, with significant reductions in angiographic and intravascular ultrasound measures of restenosis. (*Circulation*. 2003;107:38-42.)

**Key Words:** stents ■ drugs ■ restenosis ■ coronary disease ■ revascularization

Although the insertion of coronary stents has improved the success of balloon angioplasty for the treatment of coronary artery disease, restenosis after the initial procedure continues to limit its effectiveness. A promising modality to inhibit restenosis is the controlled release of paclitaxel from coronary stents.<sup>1,2</sup> Paclitaxel interferes with microtubule function, affecting mitosis and extracellular secretion, and thereby interrupts the restenotic cascade at multiple levels.<sup>3,4,5</sup> Results from animal models have shown reduced neointimal responses after local paclitaxel delivery to the vessel. A vascular compatible polymer has been developed that provides early, controlled release of paclitaxel.

The purpose of TAXUS I was to provide the first in-human clinical evaluations of a polymer-based paclitaxel-eluting stent in a randomized, multicenter trial comparing the TAXUS NIRx stent with bare metal NIR (control) stents (both from Boston Scientific Corp).

## Methods

### Device Description

The NIR stent is an uncoated, balloon-expandable stent made of 316LS surgical-grade stainless steel. The TAXUS NIRx stent is the aforementioned stent coated with paclitaxel ( $1 \mu\text{g}/\text{mm}^2$  paclitaxel per unit of stent surface area) in a slow-release formulation of a proprietary polymer (hydrocarbon-based elastomer). Both the coated and uncoated stents were available in 15-mm lengths and either 3.0- or 3.5-mm diameters and were hand-mounted onto the balloon delivery catheter.

### Study Population

Between October 2000 and March 2001, 61 patients were randomized to either a single TAXUS paclitaxel-eluting stent or a control (bare metal NIR) stent. The trial was conducted at three German heart centers after the approval of the local ethics committee and informed consent of all subjects had been obtained. Target lesions were single de novo or restenotic coronary lesions. Angiographic inclusion criteria were lesion length  $\leq 12$  mm, 50% to 99% diameter stenosis, and vessel diameter between 3.0 mm and 3.5 mm. Patients

Received September 19, 2002; revision received October 24, 2002; accepted October 24, 2002.

From the Heart Center Siegburg (E.G., R.M., L.B., U.G.), Siegburg, Germany; Klinik Dr. Mueller (S.S.), Muenchen, Germany; Krankenhaus der Barmherzigen Brüder (K.E.H.), Trier, Germany; and Boston Scientific Corp (M.E.R.), Natick, Mass.

This article originally appeared Online on November 25, 2002 (*Circulation*. 2002;106:r76-r80).

Correspondence to Eberhard Grube, MD, FACC, FACA, Department of Cardiology/Angiology, Heart Center Siegburg, Ringstrasse 49, 53721 Siegburg, Germany. E-mail GrubeE@aol.com

© 2003 American Heart Association, Inc.

*Circulation* is available at <http://www.circulationaha.org>

DOI: 10.1161/01.CIR.0000047700.58683.A1

were not eligible for enrollment if they had a history of acute myocardial infarction; a left ventricular ejection fraction <30%; a stroke within the previous 6 months; renal dysfunction, as defined by serum creatinine >1.7 mg/100 mL; or contraindication to aspirin, clopidogrel, or ticlopidine. Target lesions requiring >1 study stent for full coverage were excluded.

**Study Administration**

This trial was conducted with a strictly double-blinded analysis. To maintain blind packaging, the TAXUS and control stents were indistinguishable by physical and radiographic appearance. The intravascular ultrasound (IVUS) and quantitative coronary angiography (QCA) core labs and the Clinical Events Committee were blinded to treatment groups.

**Stenting Procedure**

Before stent implantation, patients were premedicated with aspirin (>80 mg), clopidogrel (300 mg), and heparin. After predilatation, study stents were deployed according to conventional techniques with IVUS guidance. Postdeployment high-pressure dilatation was at the investigator’s discretion. During the procedure, intravenous heparin was given to maintain an activated clotting time ≥250 seconds. One study stent was allowed; use of additional nonstudy stents was at the investigator’s discretion. After stent implantation, aspirin (>80 mg/d) was administered for at least 12 months and clopidogrel (75 mg/d) for 6 months.

**Follow-Up**

Clinical evaluation was scheduled at 1, 6, 9, and 12 months after implantation. Angiographic and IVUS imaging was performed before stent implantation, after the procedure, and at 6 months’ follow-up.

**Primary End Point**

Major adverse cardiac events (MACE), including death from any cause, Q-wave myocardial infarction, target vessel revascularization, and stent thrombosis at 30 days, were defined as the primary end point of this trial. Q-wave myocardial infarction was defined as development of Q waves in ≥2 contiguous leads with postprocedural creatine kinase and isoenzyme (CK-MB) levels elevated above normal. Target vessel revascularization was subclassified as CABG surgery, percutaneous intervention on the target lesions (target lesion revascularization [TLR]) or percutaneous intervention on the non-target lesion. An independent Clinical Events Committee adjudicated adverse events, including MACE.

**Angiographic and IVUS Analysis**

Coronary angiograms were obtained in multiple views after intracoronary injection of nitroglycerin. Angiograms and IVUS images were analyzed according to previously published methods by an independent core laboratory (Heart Core, Leiden, the Netherlands). Quantitative coronary angiographic end points included binary restenosis, defined as >50% diameter stenosis; reference vessel diameter (RVD); minimum lumen diameter (MLD); percent diameter stenosis (%DS); late lumen loss; and late loss index. Late lumen loss was measured as the difference between postintervention MLD and MLD at follow-up. RVD, MLD, and %DS were measured before the procedure, after the procedure, and at follow-up.

IVUS images were acquired after the procedure and at the 6-month follow-up visit with the use of automated pull-back after intracoronary administration of nitrates. A computer-based contour detection program was used for automated 3D reconstruction of the segment. Lumen, stent boundaries, and external elastic membrane were detected with a minimum cost algorithm, and volumetric quantification was performed. The total analysis segment included the stented segment as well as the margins 5 mm distal and proximal to the stents.

**TABLE 1. Baseline Demographics and Clinical Characteristics**

Baseline Demographics	TAXUS*	NIR Control*	P
Male sex	94%	83%	0.255
Age, y	66±6.8	63.8±7.8	0.236
Prior myocardial infarction	26%	30%	0.780
Congestive heart failure	0%	0%	NA
Current hypertension	65%	63%	1.0
Current hypercholesterolemia	81%	81%	1.0
Diabetes	23%	13%	0.507
Smoking history	54%	47%	0.793
Silent ischemia	23%	37%	0.211
CCS angina classification			0.163
1	0	7	
2	61	33	
3	10	20	
4	16	17	
None	13	23	

NA indicates not applicable because of zero value; CCS, Canadian Cardiovascular Society.

\*Values are given as percentages (count/sample size) unless indicated otherwise.

**Statistical Analysis**

Quantitative data are presented as rates or mean value±SD. Probability values are 2-sided from Student’s *t* test for continuous variables and Fisher’s exact test for categorical variables. A value of *P*<0.05 was considered significant. The statistical analysis was performed with the aid of commercially available software (SAS Version 6.12).

**Results**

**Demographics**

A total of 61 patients were enrolled (TAXUS, n=31; control, n=30). Fifty-nine patients had de novo lesions, and 2 had restenotic lesions. Baseline clinical characteristics and QCA-determined lesion characteristics were similar between the 2 groups (Tables 1 and 2). There was a trend toward a greater use of the TAXUS stent in the left anterior descending artery (LAD) and more severe angina in the control group (*P*=NS).

**Clinical MACE Results**

The procedural and technical success rate was 100% for both groups. Nonstudy stents were implanted to optimize results in

**TABLE 2. Baseline Lesion Characteristics**

Baseline Lesion Characteristics	Taxus	NIR Control	P
Target vessel			0.090
LAD	54.8%	26.7%	
Left circumflex	22.6%	36.7%	
Right coronary artery	22.6%	36.7%	
Type of lesion*			0.200
A	32.3%	13.3%	
B1	38.7%	43.3%	
B2	29.0%	43.3%	
C	0.0%	0.0%	

\*Values given as count/sample size.

**TABLE 3. MACE and Stent Thrombosis at 1-Year Follow-Up**

MACE Event	TAXUS	NIR Control	<i>P</i>
12-Month MACE rate	3% (1/30)	10% (3/30)*	0.612
Death	0	0	NA
Q-wave myocardial infarction	0	0	NA
Percutaneous coronary intervention—target vessel	3%	10%	0.612
Target lesion	0%	10%	0.237
Nontarget lesion	3%	0%	1.000
CABG	0%	3%	1.000
Stent thrombosis	0%	0%	NA

NA indicates not applicable because of zero value.

\*There were a total of 4 MACE events in 3 patients (0.13 event frequency). One patient had 2 events.

4 patients in the TAXUS group and 6 in the control group. The 30-day MACE rate was 0% in both groups.

The 6-month MACE rate was 0% (0 of 31 patients) in the TAXUS group compared with 7% in the control group (2 of 30 patients) ( $P=NS$ ). These two MACE events in the control group were TLRs. One patient had LAD in-stent restenosis with unstable angina at 106 days treated by PTCA. This patient subsequently had CABG at 198 days for recurrent restenosis adjudicated as a second MACE event. The second patient had recurrent angina at 167 days associated with LAD in-stent restenosis treated with atherectomy. As shown in Table 3, the 12-month MACE rate in the control group was 10% (4 events in 3 patients) in comparison with 3% (1 event) in the TAXUS group ( $P=NS$ ).

### Baseline Lesion Characteristics

Acute angiographic results were comparable between the two groups, as shown in Table 4. The mean RVD after the procedure was  $2.99\pm 0.46$  mm, with lesion lengths of  $10.70\pm 3.27$  mm in the TAXUS group. This was similar to the

**TABLE 4. QCA Results**

QCA In-Stent Lesion Characteristics	TAXUS	NIR Control	<i>P</i>
Before intervention			
RVD, mm	$2.99\pm 0.46$ (31)	$2.94\pm 0.52$ (29)	0.699
MLD, mm	$1.30\pm 0.4$ (31)	$1.23\pm 0.43$ (29)	0.557
%DS	$56.51\pm 12.26$ (31)	$57.82\pm 13.24$ (29)	0.692
Lesion length, mm	$10.70\pm 3.27$ (31)	$11.89\pm 4.93$ (29)	0.272
After intervention			
MLD, mm	$2.95\pm 0.34$ (31)	$2.87\pm 0.43$ (27)	0.443
%DS	$6.12\pm 9.49$ (31)	$9.84\pm 7.06$ (28)	0.096
6-Month follow-up			
MLD, mm	$2.60\pm 0.49$ (30)	$2.19\pm 0.65$ (29)	0.007
RVD, mm	$3.02\pm 0.47$ (30)	$3.01\pm 0.53$ (29)	0.899
%DS	$13.56\pm 11.77$ (30)	$27.23\pm 16.69$ (29)	<0.001
>50% Restenosis	0% (0/30)	10% (3/29)	0.112
Late lumen loss, mm	$0.36\pm 0.48$ (30)	$0.71\pm 0.47$ (26)	0.008
Loss index	$0.22\pm 0.29$ (30)	$0.45\pm 0.29$ (26)	0.004

control group RVD of  $2.94\pm 0.52$  mm and lesion length  $11.89\pm 4.93$  mm.

### Six-Month Angiographic Results

The 6-month angiographic in-stent binary restenosis rate was 10% (3 of 29 patients) for the control stent and 0% (0 of 30 patients) for the TAXUS stent ( $P=NS$ ). Mean %DS at 6 months was significantly lower in the TAXUS group than in the control group (13.56% versus 27.23%,  $P<0.001$ ). The MLD was significantly larger in the TAXUS group than in the control group (2.60 mm versus 2.19 mm;  $P=0.007$ ). Late lumen loss and loss index were significantly improved in the TAXUS group (all  $P<0.009$ , Table 4).

As shown in the Figure, there was a significant improvement in the %DS within the stented area with no differences at the proximal and distal edges (5 mm from the stent margins) between the TAXUS and control groups.

### Six-Month IVUS Results

The baseline IVUS characteristics were similar in both groups (Table 5). After the procedure, no significant differences were noted between the groups for minimal lumen area or neointimal hyperplasia. At 6 months after the procedure, the mean minimal lumen area in the TAXUS group was significantly larger than in the control group ( $5.6$  mm<sup>2</sup> versus  $4.8$  mm<sup>2</sup>,  $P=0.027$ ). Neointimal hyperplasia was significantly less in the TAXUS group than in the control group ( $14.8$  mm<sup>3</sup> versus  $21.6$  mm<sup>3</sup>,  $P=0.028$ ).

### Covariate Analysis

Covariate analysis showed patients with concentric stenosis had lower late loss values than did those with eccentric stenosis ( $P=0.02$ ). Other covariates, including diabetes, smoking, vessel location, tortuosity, and calcification, were not predictive of angiographic or IVUS outcomes.

### Discussion

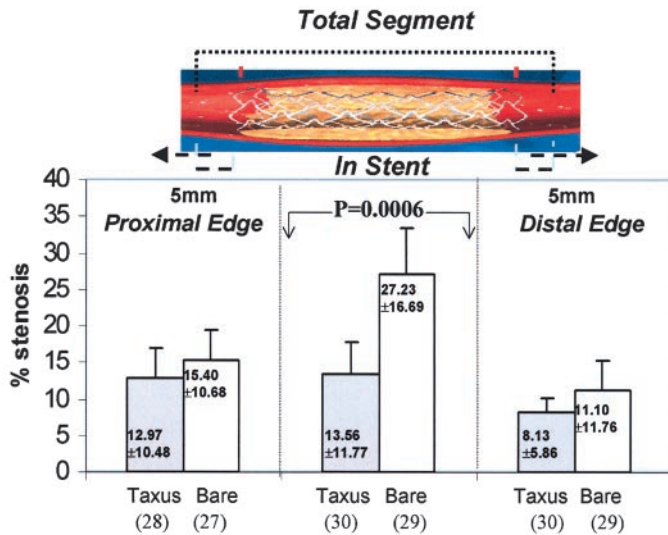
This randomized, double-blind feasibility trial supports safety of the slow-release formulation of the TAXUS paclitaxel-eluting coronary stent in the treatment of coronary lesions at 1 year. There were no early or late stent thromboses in any study subject. MACE rates were low at 30 days, 6 months, and 12 months. The binary restenosis rate was 0% at 6 months; only 1 patient in this group had a target vessel revascularization, and that was for a lesion distal to the stented area.

Despite the small number of patients and excellent results in the control group, promising efficacy for the TAXUS slow-release formulation is supported by significant and concordant improvements in the QCA and IVUS parameters.

At 6 months, there were reductions in the %DS and late lumen loss compared with the control stent. This was confirmed by the IVUS data showing improvements in the minimal lumen area and normalized neointimal hyperplasia.

This drug-eluting stent system takes advantage of the antineoplastic agent paclitaxel incorporated into a unique slow-release, hydrocarbon-based elastomer polymer system to produce a controlled, biphasic release of this medication into the surrounding tissue. Paclitaxel is a microtubule-

### Six-Month Edge Analysis: % Diameter Stenosis



Six-month %DS comparing in-stent and edge results. Error bars reflect 2× the standard error.

stabilizing agent with potent activity against proliferation, migration, and signal transduction.<sup>3,5,6,7</sup> The biphasic polymer-controlled drug release of this stent design, providing an early burst release in the first 48 hours followed by a slow release for the subsequent 10 days, appears to attenuate neointimal formation. Blood samples showed no systemic levels of paclitaxel with this slow-release formulation.

Several studies evaluating drug-eluting stents loaded with different antiproliferative agents, such as sirolimus, have recently been published or are still ongoing (Randomized study with the sirolimus-eluting Bx VELOCITY balloon-expandable stent [RAVEL], SIROLImUS-coated Bx Velocity stent in the treatment of patients with de novo coronary artery lesions [SIRIUS]).<sup>8</sup> Reported by Sousa et al,<sup>9</sup> the first in-human experience with a sirolimus-coated stent confirmed a profound reduction of neointimal volume with absence of stent restenosis for up to 1 year in the drug-coated stent group. The randomized, multicenter RAVEL trial compared a

bare metal stent and the sirolimus-coated BX Velocity stent (140 μg/cm<sup>2</sup>), demonstrating at 6 months' follow-up a restenosis rate of zero in the drug-coated stent group and a lumen loss of -0.01±0.33 mm in the sirolimus group versus 0.80±0.53 mm in the control group. There was no TLR, and the event-free survival rate at 1 year was 94.1% versus 70.9%.<sup>10</sup>

The persistence of extremely low MACE rates without stent thrombosis or TLR at 12 months in TAXUS I is encouraging. These promising data contrast with reports on the QuaDDs stent system, a high-capacity delivery system involving ≤5 polymeric sleeves per stent to provide ≤4000 μg of 7-hexanoyl taxol (QP2, a taxane derivative). Two problems have been reported: very late stent thrombosis (>6 months after implantation) and disappointing 12-month restenotic findings.

Liistro et al<sup>11</sup> reported a case of late total occlusion, 7 months after implantation of a QP2-eluting stent, presenting

**TABLE 5. IVUS Results**

IVUS In-Stent Lesion Characteristics	TAXUS	NIR Control	P
Before intervention			
MLA, mm <sup>2</sup>	3.2±0.6	2.9±0.5	0.123
Vessel volume, mm <sup>3</sup>	232.9±65.4	196.9±69.8	0.081
Lumen volume, mm <sup>3</sup>	86.9±20.8	74.1±24.0	0.062
After intervention			
MLA, mm <sup>2</sup>	6.97±1.69	6.36±1.55	0.165
Normalized vessel volume, mm <sup>3</sup>	282.1±70.1	261.8±70.4	0.294
Normalized lumen volume, mm <sup>3</sup>	119.1±27.7	113.0±25.2	0.408
6-Month follow-up			
MLA, mm <sup>2</sup>	5.6±1.2	4.8±1.3	<0.027
Normalized vessel volume, mm <sup>3</sup>	286.0±50.3	270.7±61.6	0.335
Normalized lumen volume, mm <sup>3</sup>	107.7±19.2	98.0±26.4	0.135
Normalized neointimal hyperplasia, mm <sup>3</sup>	14.8±10.8	21.6±10.7	0.028

MLA indicates minimal lumen area.

as an acute coronary syndrome after interruption of ticlopidine treatment. One potential mechanism for the very late thrombosis could be discontinuation of antiplatelet therapy when ongoing drug effect prevented adequate neointimal coverage over bare stents to pacify the surface. Liistro et al<sup>12</sup> have also reported results from a 15-patient, single-arm, in-stent restenosis registry in which acceptable 6-month outcomes were followed by disappointing 12-month restenotic data in  $\approx 60\%$  of patients. These reports suggest that the polymer sleeves, milligram doses of 7-hexanoyl taxol, and/or protracted drug delivery from the stent could delay healing or even aggravate the restenotic process.

The design objective of the TAXUS stent system is to use the minimum effective dose for the shortest duration by controlled biphasic drug delivery targeted for the initial phase of the restenotic process. In the TAXUS I study, the absence of TLR at 12 months suggests that the amount and rate of paclitaxel release disrupts the restenotic cascade while allowing sufficient neointimal growth to promote healing and avoid late thrombosis. Ongoing clinical follow-up in the present and the ongoing TAXUS trials on the NIR stent platform (TAXUS II, III) or the EXPRESS stent platform (TAXUS IV, VI) for more complex lesions should provide data on the clinical value of the technology.<sup>8</sup>

### Limitations

Although the present study was a prospective, multicenter, double-blind, randomized trial, several limitations are noteworthy. The trial was conducted at only 3 sites where 31 patients with standard-risk lesions received the slow-release formulation of the TAXUS stent. The control group had excellent clinical and angiographic outcomes that may have limited the ability to identify significant differences with the TAXUS stent. IVUS guidance and extended use of clopidogrel may have contributed to the strong performance in both groups.

Other limitations include the prohibition of multiple stenting and the exclusion of high-risk patients. Given their high restenosis rates, high-risk patients are most likely to realize the greatest benefit from drug-eluting stents. Hand-crimping was employed in this study, potentially introducing the risk of drug displacement and contamination. Nonetheless, no MACE were clearly attributable to such potential risks.

### Conclusion

In this feasibility trial, the slow-release formulation of the TAXUS stent offers the possibility of delivering paclitaxel to the target lesion and inhibiting postprocedural neointimal proliferation without adverse local or systemic effects. Larger studies of this promising technology are needed.

### Acknowledgments

This study was supported by Boston Scientific Corp. We thank Michael Coughan and Monika Hanisch for their assistance in conducting the study.

### References

1. Drachman DE, Edelman ER, Seifert P, et al. Neointimal thickening after stent delivery of paclitaxel: change in composition and arrest of growth over six months. *J Am Coll Cardiol*. 2000;36:2325–2332.
2. Herdeg C, Oberhoff M, Baumbach A, et al. Local paclitaxel delivery for the prevention of restenosis: biological effects and efficacy in vivo. *J Am Coll Cardiol*. 2000;35:1969–1976.
3. Axel DI, Kunert W, Goggelmann C, et al. Paclitaxel inhibits arterial smooth muscle cell proliferation and migration in vitro and in vivo using local drug delivery. *Circulation*. 1997;96:636–645.
4. Giannakakou P, Robey R, Fojo T, et al. Low concentrations of paclitaxel induce cell type-dependent p53, p21 and G1/G2 arrest instead of mitotic arrest: molecular determinants of paclitaxel-induced cytotoxicity. *Oncogene*. 2001;20:3806–3813.
5. Hui A, Min WX, Tang J, et al. Inhibition of activator protein 1 activity by paclitaxel suppresses interleukin-1-induced collagenase and stromelysin expression by bovine chondrocytes. *Arthritis Rheum*. 1998;41:869–876.
6. Jackson JK, Tudan C, Sahl B, et al. Calcium pyrophosphate dihydrate crystals activate MAP kinase in human neutrophils: inhibition of MAP kinase, oxidase activation and degranulation responses of neutrophils by taxol. *Immunology*. 1997;90:502–510.
7. Belotti D, Vergani V, Drudis T, et al. The microtubule-affecting drug paclitaxel has antiangiogenic activity. *Clin Cancer Res*. 1996;2:1843–1849.
8. Hiatt B, Ikeno F, Yeung A, et al. Drug-eluting stents for the prevention of restenosis: in quest for the Holy Grail. *Catheter Cardiovasc Interv*. 2002;55:409–417.
9. Sousa JE, Costa MA, Abizaid A, et al. Lack of neointimal proliferation after implantation of sirolimus-coated stents in human coronary arteries: a quantitative coronary angiography and three-dimensional intravascular ultrasound study. *Circulation*. 2001;103:192–195.
10. Morice MC, Serruys PW, Sousa JE, et al, for the RAVEL Study Group. A randomized comparison of a sirolimus-eluting stent with a standard stent for coronary revascularization. *N Engl J Med*. 2002;346:1773–1780.
11. Liistro F, Colombo A. Late acute thrombosis after paclitaxel eluting stent implantation. *Heart*. 2001;86:262–264.
12. Liistro F, Stankovic G, Di Mario C, et al. First clinical experience with a paclitaxel derivate-eluting polymer stent system implantation for in-stent restenosis: immediate and long-term clinical and angiographic outcome. *Circulation*. 2002;105:1883–1886.